

구강내 접근법을 이용한 비순낭종의 치료 경험

권준성¹ · 최환준¹ · 최창용¹ · 박재홍² · 박래경³ · 김 숙⁴

순천향대학교 의과대학 성형외과학교실¹, 이비인후과학교실², 외과학교실³, 병리학교실⁴

Clinical Experience with Nasolabial Cysts Using the Sublabial Approach

Joon Sung Kwon, M.D.¹, Hwan Jun Choi, M.D.¹,
Chang Yong Choi, M.D.¹, Jae Hong Park, M.D.²,
Nae Kyeong Park, M.D.³, Sook Kim, M.D.⁴

Department of Plastic and Reconstructive Surgery¹,
Otolaryngology-Head and Neck Surgery², General Surgery³,
and Pathology⁴, College of Medicine, Soonchunhyang
University, Korea

Purpose: A nasolabial cyst is a rare non-odontogenic, soft-tissue, developmental cyst arising anywhere on the face inferior to the nasolar region. It is thought to arise from either epithelial remnants trapped along the lines of fusion during the development of face or the remnants of the developing nasolacrimal duct. This study examines various features of nasolabial cysts with bony involvement to provide a basis for correct diagnosis and treatment.

Methods: Eight cases of nasolabial cyst treated in Soonchunhyang Hospital between March 2002 and July 2010 were examined in terms of their clinical features and radiological and histological findings. Seven patients underwent surgical excision of the cyst via an intraoral, sublabial approach. One underwent incision and drainage.

Results: Our eight patients were seven women and one man. The most frequent symptoms and signs were facial deformity and swelling of the nasolabial fold. Computed tomography (CT) showed a well-circumscribed cystic mass lateral to the pyriform aperture. Seven cases had erosive lesions on CT, and the intraoperative findings were consistent with a nasolabial cyst with a bony defect. Typical histopathological findings showed that these cysts were most frequently lined with respiratory epithelium with

ciliated columnar cells and cuboid cells. No patient developed complications or recurrences.

Conclusion: A nasolabial cyst is often unrecognized or confused with other intranasal masses, including fissural and odontogenic cysts, midface infections, or swelling in the nasolabial area. Therefore, a careful clinical and radiological evaluation should be preformed when considering the differential diagnosis. We present eight patients with nasolabial cysts treated via a gingivobuccal approach with excellent functional and cosmetic results.

Key Words: Nasolabial, Developmental, Congenital, Cyst

I. INTRODUCTION

Nasolabial cysts are rare, but easily identifiable when they occur.¹ They are soft-tissue, developmental epithelial cysts that characteristically occur as a swelling in the nasolabial fold at the base of the alae of the nose.² They are thought to arise from the remnants of the nasolacrimal ducts and are the result of an ectodermal developmental swelling that manifests as a mass on the lateral half of the floor of the nasal vestibule at the base of the nasal ala. Most of our knowledge of these cysts is limited to isolated case reports.¹ The nasolabial cyst, also called a nasoalveolar cyst, is a benign entity that grows under the mucosa of the nostril floor, often appearing as a bulge in the alveolabial sulcus.³ Its intranasal extension is usually confined to the lateral half of the anterior nasal floor, extending into the inferior meatus.¹⁻⁶ The lesion is often unilateral, but may be bilateral.^{4,5} It may cause facial asymmetry and minor discomfort, and may be painful if infected.⁵⁻⁸

This article describes our retrospective analysis of the clinical appearances, pathological findings, and treatment results in eight cases of nasolabial cyst to assist plastic surgeons in the diagnosis and treatment of this rare entity. Seven patients underwent excision via a sublabial approach. Our findings of adult onset, higher incidence among women, and right-side preponderance concurred with current opinion.

Received October 25, 2010

Revised April 13, 2011

Accepted April 15, 2011

Address Correspondence: Hwan Jun Choi, M.D., Ph.D., Department of Plastic & Reconstructive Surgery, Soonchunhyang University Cheonan Hospital, Soonchunhyang University College of Medicine, 23-20 Bongmyung-dong, Cheonan 330-721, Korea. Tel: (041) 570-2195/Fax: (041) 574-6133/E-mail: medi619@hanmail.net

II. MATERIALS AND METHODS

Between March 2002 and July 2010, we used a sublabial approach to nasolabial cysts in eight consecutive patients (Table I). The diagnosis in each had been established by correlating the clinical, histological, and in almost all cases, radiographic findings. Information on the clinical picture, presenting symptoms, size, and location of the cyst and treatment was obtained from a retrospective review of each patient's medical record. In four of eight cases excision was carried out under general anesthesia, 3 under local anesthesia and in the remaining 1 incision and drainage was carried out without anesthesia.

First, the nasal cavities and oral cavity were cleaned. The nasal cavities were anesthetized topically, and the mucosa were decongested with cotton gauze soaked in a solution of 2% lidocaine and 0.05% epinephrine. An incision was made in the gingivolabial fold over the convexity of the swelling. A linear incision above the gingival border was made, starting from the frenulum labiorum and extending to the first premolar. Instrument separation was needed only at the point of contact of the lesion membrane with the tissues of the lip and nasal cavity. The portion overlying the alveolar bone was dislodged by simply lifting the lip. There was no resistance indicating adherence. The cyst was removed by meticulous dissection. Because the cyst was usually closely related to the floor of the nose, it was sometimes necessary to remove some nasal mucosa to remove the cyst entirely. Very small perforations could be left untreated, and relatively large ones were treated with absorbable sutures or nasal packing. The incision was closed with interrupted 4-0 absorbable sutures. Loose

nasal packing was applied at the end of the operation and removed 2 days later.

III. RESULTS

The eight patients were seven women and one man. The patients' ages ranged from 24 to 64, with a mean age of 45.3. The cysts were located on the right side in five (63%) and the left in three (38%). The duration of symptoms at the time of presentation ranged from 1 week to 5 years. All patients were monitored via outpatient clinic visits and telephone calls. The most common complaint was swelling in the nasolabial region in seven patients (88%), followed by nasal obstruction or pain in four (50%) and denture problems in three (38%) (Table II). In addition, most of the patients had a history of intermittent swelling over the nasolabial area. This was usually characterized by a painless lump beneath one ala of the nose, and in some patients, by protrusion of the upper lip or effacement of the nasolabial fold with minor discomfort. The sizes of the cysts, as estimated from computed tomography (CT), ranged from 0.8 to 2 cm in diameter. Seven patients underwent CT, which typically showed a well-demarcated, low-density, cystic lesion lateral to the pyriform aperture. Invasion of the adjacent maxillary bone was observed and abnormalities of the alveolar bone were detected in all eight cases. Endoscopic views of patients with nasal obstruction show intranasal extension to the lateral half of the anterior nasal floor.

The cysts were completely extraosseous, with no attachment to the underlying bone and were easily dissected from it. In all cases, the mucosa had healed well by the 2 week follow-up, regardless of whether the cyst was repaired primarily. In one infected cyst, the

Table I. Summary of the Patients

Case	Sex/age	Location	Size (cm)	Treatment	Anesthesia	Follow-up (months)
1	F/63	Right	1.5 × 2 × 1	Excision	Local	15
2	F/64	Right	1 × 1 × 1.5	Excision	Local	60
3	F/24	Left	0.8 × 0.8 × 0.3	Incision and drainage	None	47
4	F/55	Right	2 × 1 × 1	Excision	General	25
5	F/35	Left	2 × 1 × 1.5	Excision	General	8
6	F/28	Left	1 × 1.5 × 0.5	Excision	Local	22
7	F/57	Right	2 × 1 × 2	Excision	General	13
8	M/36	Right	2 × 2 × 1.5	Excision	General	6
Averages	45.3					24.5

Table II. Summary of the Clinical Features of Eight Patients with Nasolabial Cysts

Characteristics	Number of patients (%)
Sex	
Female	7 (88)
Male	1 (13)
Age (yr)	
0 ~ 19	0 (0)
20 ~ 39	4 (50)
40 ~ 59	2 (25)
60 ~ 79	2 (25)
Location	
Left	3 (63)
Right	5 (28)
Both	0 (0)
Presenting features	
Nasolabial swelling or mass	7 (88)
Infection	2 (25)
Nasal obstruction	4 (50)
Pain	4 (50)
Epistaxis	1 (13)
Discharge	1 (13)
Denture problem	3 (38)
Bony erosion or indentation	
Yes	7 (88)
No	1 (13)

mucoid discharge was turbid. This patient underwent incision and drainage only. The cyst was infected at the initial presentation, with acute enlargement, pain, and erythema, and an antibiotic was prescribed for about 2 weeks. 2 weeks later, most of these symptoms subsided. The patient was followed up via outpatient clinic visits. No recurrence was found during the follow up. Histopathologically, the inner lining of the nasolabial cysts was mainly respiratory epithelium with ciliated columnar cells and cuboid cells. These patients have been followed up from 6 to 60 months, with an average of 24.5 months. No postoperative complications or other recurrences were reported.

A. Case 2

A 64-year-old female presented with a growing right

nasal swelling of 2 years' duration that caused problems with her dentures. On physical examination, her upper lip was mildly protuberant and there was lateral displacement of the right nasal ala. The patient was edentulous, and a fluctuant lesion measuring 1.5 cm in diameter was observed in the upper gingivolabial sulcus near the right incisor and canine. The patient's medical history was unremarkable (Fig. 1).

B. Case 5

A 35-year-old female presented with a 5-year history of a painless lump on the left side of the upper lip. Questioning revealed that the mass had developed slowly, and over the last year, she had experienced episodes of mild nasal obstruction and significant nasal asymmetry. No specific medical or family history was present. On physical examination, a 2 × 1.5-cm soft, well-defined mass was observed on the left side of the nostril. Her nostril was wide open and projected forward, and the lower portion of the nose was very broad. The columella and nasal tip were tilted upward, and there was marked prominence and fullness around the central and upper portion of the lip, producing a blunt nasolabial angle. Preoperative CT showed a left-side cystic mass and bony erosion of the maxilla, with a mass protruding into the anterior nasal floor. The postoperative course was uncomplicated (Fig. 2).

C. Case 8

A 36-year-old man had a swelling of the right nasolabial area, which had been present for about 6 months. It was tender and concerned him for purely cosmetic reasons. Examination revealed a 2-cm swelling in the region of the right nasolabial fold that protruded into the floor and lateral nasal vestibule. The nasal mucosa was intact. There was slight lifting of the right ala of the nose. Bimanual palpation revealed fluctuance between the nasolabial area and buccal sulcus (Fig. 3).

IV. DISCUSSION

The nasolabial cyst has been called many names, including the nasoalveolar cyst, nasal vestibule cyst, nasal wing cyst, and mucoid cyst of the nose.² Its pathogenesis is unknown.¹ It is usually situated behind the ala nasi, extending backward beneath the nasal floor into the inferior meatus and forward into the labio-gingival sulcus behind the upper lip.⁴ The location of the cyst corresponds with a possible origin from the remnants of the nasolacrimal duct.⁹ This theory is, to

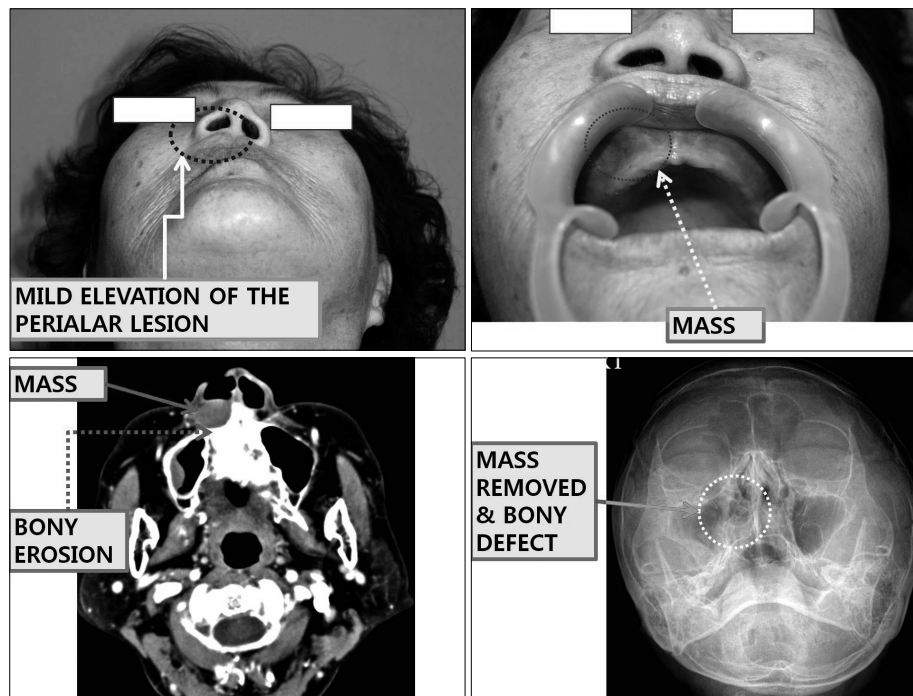


Fig. 1. Case 2. A 64-year-old female. (Above, left) Preoperatively, there is mild elevation of the right peri-alar region. (Above, right) The mass is seen in the right gingivobuccal area. (Below, left) Preoperative enhanced axial CT shows a well-defined, ovoid, soft-tissue cystic lesion (1 × 1 × 1.5 cm) with bony involvement. (Below, right) A simple x-ray obtained immediately postoperatively reveals maxillary indentation.

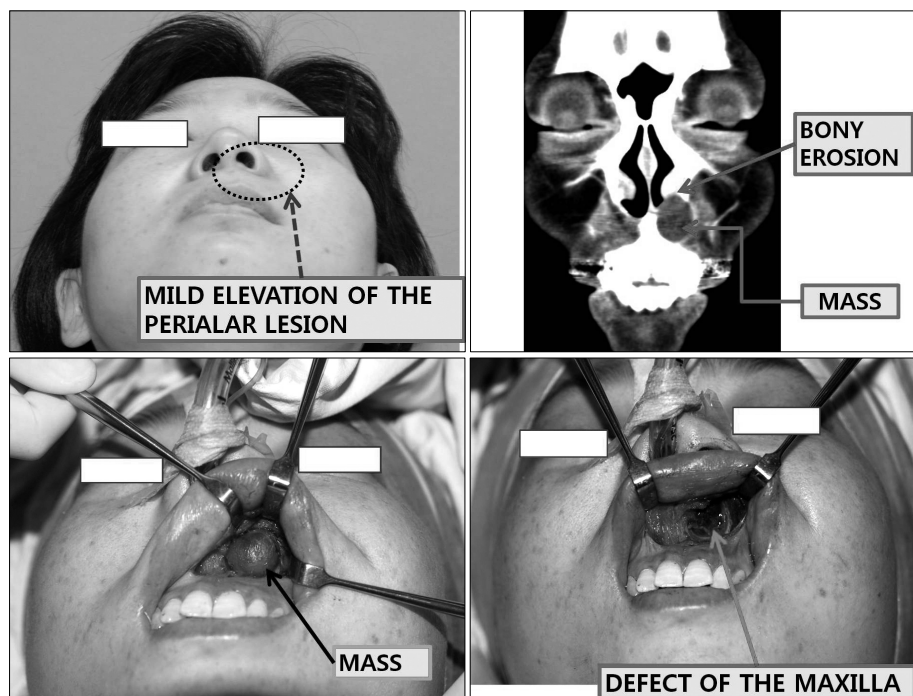


Fig. 2. Case 5. A 35-year-old female. (Above, left) Mild elevation of left side peri-alar region. (Above, right) The facial CT sagittal view reveals a 1.5-cm round, cystic mass in the left anterior nasal floor with adjacent bony erosion. (Below, left) Intraoperatively, a well-margined cystic mass is seen. (Below, right) After excising the cystic lesion under general anesthesia, a defect and erosion of the maxilla are seen intraoperatively.

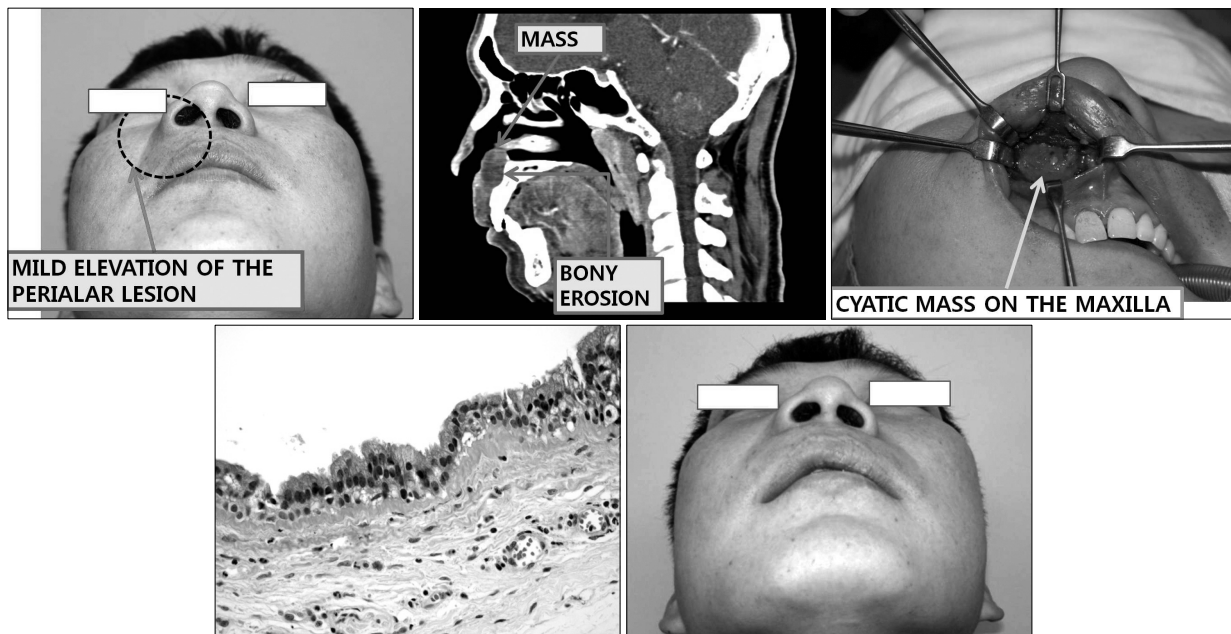


Fig. 3. Case 8. A 36-year-old male had a cystic mass in the right peri-alalar area. (Above, left) The nasal deformity due to a bulging soft tissue mass in the right nasolabial groove and nasal vestibule. (Above, center) Preoperative enhanced sagittal CT reveals a round cystic mass at the anterior nasal floor and bony erosion of the underlying maxilla. (Above, right) A linear incision was made above the gingival border, from the frenulum labiorum to the premolar. Instrument separation was needed only at the point of contact of the lesion membrane with the tissues of the lip and the nasal cavity. (Below, left) On pathologic finding, the cyst was lined by pseudostratified columnar or cuboidal epithelium (Hematoxylin and eosin stain, $\times 400$). (Below, right) In the long-term, normalization of the nasolabial groove and nasal vestibule are seen.

some extent, supported by the fact that the mature nasolacrimal duct is lined by pseudostratified columnar epithelium and that this is the type of epithelial lining most commonly found in the nasolabial cyst.⁹ Facial deformity can occur if a cyst enlarges anteriorly. The main symptom of a nasolabial cyst, if present, is swelling, mainly in the region of the nasal vestibule.⁵⁻⁹ The mass extends inferiorly into the gingivobuccal sulcus or laterally into the facial soft tissues and causes widening of the nasal vestibule, swelling of the upper lip, obliteration of the nasolabial fold, elevation of the nasal floor, and swelling in the nasal and oral cavity.¹⁻¹⁰ The elevation and medialization of the inferior turbinate can cause nasal obstruction. Pain is uncommon, unless the cyst is infected secondarily.^{1,3,7,8} Such an infection can be initiated by trauma or surgical intervention, such as aspiration or incision.¹ In our series, swelling of the nasolabial fold was the most common complaint, followed by nasal obstruction and pain. The cysts are best palpated bimanually with one finger in the floor of the nasal vestibule, and another in the labial sulcus. Palpation of the mass confirms a firm smooth, spherical, fluid-filled structure that may or may not be tender. Nasolabial cysts are usually unilateral,¹⁻¹⁰ and bilateral

cysts are rare.^{3,5,8,9} Over several years, the swelling may enlarge slowly and painlessly, although patients may present with an acutely painful swelling if the cyst becomes infected. Less commonly, the extension of infection from these cysts may mimic facial cellulitis, a periodontal abscess, acute maxillary sinusitis, or a nasal furuncle.⁷ A swelling in the maxillary buccal sulcus may prevent seating of a denture. The cysts may produce pressure erosion of the underlying bone, and they may grow quite large and erode the maxillary alveolus.⁸ The cystic contents are typically mucoid or serous, unless infected or hemorrhagic. Nasolabial cysts are not obvious on plain radiographs, but radiographs may show bony rarefaction and deformity of the lateral and anterior edges of the nasal floor.^{8,10} Because the features of these cysts are non-specific on radiological imaging, such investigations rarely provide information that aids with the clinical diagnosis or influences their subsequent management.⁷ Typically, these cysts are located anterior to the pyriform aperture on CT. Nonetheless, long-standing masses may cause remodeling of the anterior maxilla. On magnetic resonance imaging (MRI), the cysts may look slightly hyperintense relative to cerebrospinal fluid (CSF) on T1-weighted images, and isointense with

CSF on T2-weighted images.¹⁰ It is important to differentiate a nasolabial cyst from other lesions that may occur at this site, such as a dental or periodontal abscess, odontogenic or nonodontogenic cyst, soft tissues masses including benign tumors (schwannomas or adenomas), or malignant tumors of the minor salivary glands.⁵⁻¹⁰

Simple surgical excision via a sublabial approach is sufficient for treatment.¹ The incision should be made in the gingivolabial fold over the convexity of the swelling, but not through the mucoperiosteum, because it is the wrong tissue plane.¹ When a cyst extends to the nasal floor, there is a risk of perforation. Large nasal defects should be repaired by suturing. All of the nasolabial cysts analyzed in our literature review were treated by either sublabial excision or transnasal marsupialization, and no recurrences were observed.⁶ The advantages of the sublabial approach include a wider surgical field and more assurance of a complete excision.⁶ Some authors have reported that the sublabial approach significantly increases the operation time, wound swelling/ tenderness, blood loss, and duration of hospitalization compared with a transnasal marsupialization approach.¹ Transnasal marsupialization converts the nasolabial cyst into an air-containing sinus that opens into the nasal floor.⁶ The nasolabial cyst is characterized by a thin epithelial lining, which may be pseudostratified or squamous in character.⁸ A respiratory type of epithelial lining with ciliated and goblet cells is the most common histological finding.⁹ Finally, because of its rarity, its pathologic features are not well known among plastic surgeons, so we have presented eight nasolabial cysts treated via a sublabial approach with excellent functional and cosmetic results.

V. CONCLUSION

The results of this study indicate that excision via a sublabial approach has remarkable benefits for the treatment of nasolabial cysts. This procedure may become the treatment of choice if further studies confirm its safety and esthetic effectiveness.

REFERENCES

1. Choi JH, Cho JH, Kang HJ, Chae SW, Lee SH, Hwang SJ, Lee HM: Nasolabial cyst: a retrospective analysis of 18 cases. *Ear Nose Throat J* 81: 94, 2002
2. Cohen MA, Hertzanu Y: Huge growth potential of the nasolabial cyst. *Oral Surg Oral Med Oral Pathol* 59: 441, 1985
3. Renard A, Morgan BL: Nasolabial cyst. case report. *Plast Reconstr Surg* 57: 240, 1976
4. Su CY, Chien CY, Hwang CF: A new transnasal approach to endoscopic marsupialization of the nasolabial cyst. *Laryngoscope* 109: 1116, 1999
5. Brandao GS, Ebling H, Faria e Souza I: Bilateral nasolabial cyst. *Oral Surg Oral Med Oral Pathol* 37: 480, 1974
6. Chen CN, Su CY, Lin HC, Hwang CF: Microdebrider-assisted endoscopic marsupialization for the nasolabial cyst: comparisons between sublabial and transnasal approaches. *Am J Rhinol Allergy* 23: 232, 2009
7. Yuen HW, Julian CY, Samuel CL: Nasolabial cysts: clinical features, diagnosis, and treatment. *Br J Oral Maxillofac Surg* 45: 293, 2007
8. Chinellato LE, Damante JH: Contribution of radiographs to the diagnosis of naso-alveolar cyst. *Oral Surg Oral Med Oral Pathol* 58: 729, 1984
9. Allard RH: Nasolabial cyst: review of the literature and report of 7 cases. *Int J Oral Surg* 11: 351, 1982
10. Ramos TC, Mesquita RA, Gomez RS, Castro WH: Transnasal approach to marsupialization of the nasolabial cyst: report of 2 cases. *J Oral Maxillofac Surg* 65: 1241, 2007