

**Abstract**

**A Clinical Study of Free Vascularized Osteocutaneous  
Fibular Transplantation in Infected Nonunion of Tibia**

**Joon-Min Song, M.D., Jin-Il Kim, M.D., Jong-Suk Park, M.D.,  
Hee Kwon, M.D., Jae-Eung Yoo, M.D., Soo-Kyoon Rah, M.D. Chang-Uk Choi, M.D.,**

*Department of Orthopedic Surgery, Soonchunhyang University, College of medicine, Korea*

February 1995 to September 1999, authors have experienced seven cases of infected nonunion of tibial fractures with associated soft tissue injury and skin defect, and have accomplished union in all cases by free vascularized fibular graft.

All grafts healed with no radiographic evidence of bone necrosis or resorption and have been able to treat large bony defect and skin defect simultaneously.

In this study, five cases of vascularized free fibular osteocutaneous flap transfer and two cases of free fibular graft are reported.

All of seven cases were infected nonunion of tibia.

The results were obtained as follows

- 1) The mean duration of the radiologic bone union was average 5.3months.
- 2) Grafted fibular has been hypertrophied, average 10.6 months.
- 3) In five cases of preservation of posterior cortex of tibia, bony union and hypertrophy of grafted bone were earlier than that two cases of complete segmental resection of tibia.
- 4) In two cases which only free vascularized fibular graft were performed because achievement of cutaneous flap was failed, authors found that soft tissue defect was filled with granulation tissue and split-thickness skin graft was possible over the granulation tissue after 3 weeks post-operatively.

---

**Key Words** : Nonunion, Tibia, Vascularized fibular transplantation

2  
3  
(split thickness skin graft)  
19 55  
31.5 12  
48 21  
(creeping substitution)

7  
1/3 가 3 , 1/3 가 4 .  
3 3.4 6  
12.7cm 17cm 7cm  
가 meter Doppler flow

(Fig. 1-A).

1995 2 1999 8

가  
0.5cm  
7 Gigli saw  
가  
(Fig. 1-B),

5

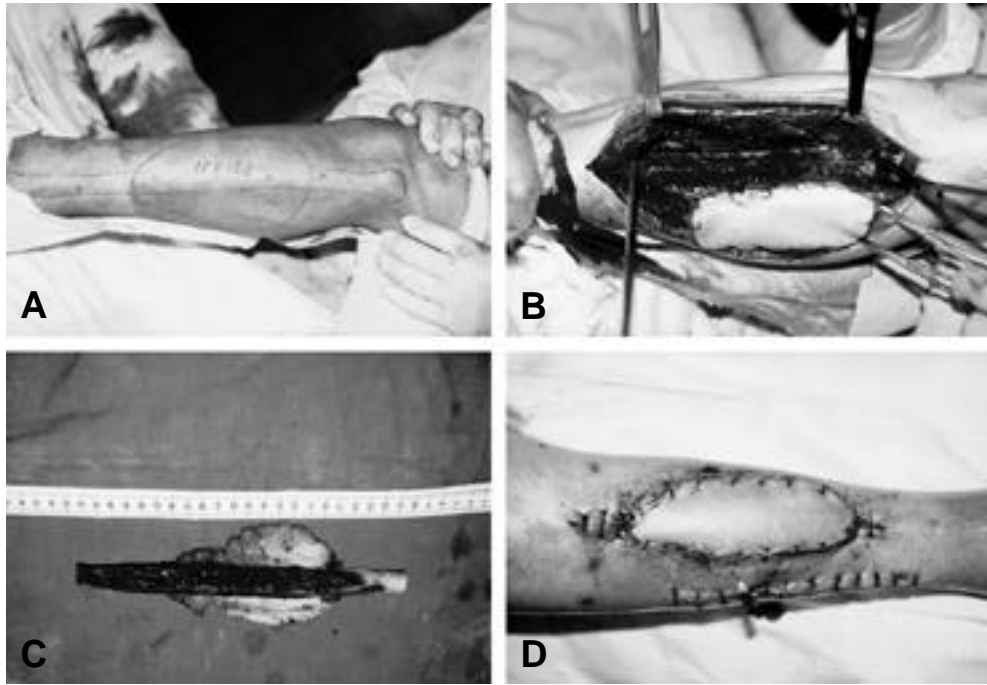


Fig. 1.

(Fig. 1-C).

0 monofilament nylon

10-  
가

6

(monofixator)  
(Fig. 1-A,B,C).

(Fig. 1-D).

16.5cm  
13cm x 6.5cm

(Fig. 1-D).

4

1

25

, 18

(Fig. 2-E,F,G,H,I).

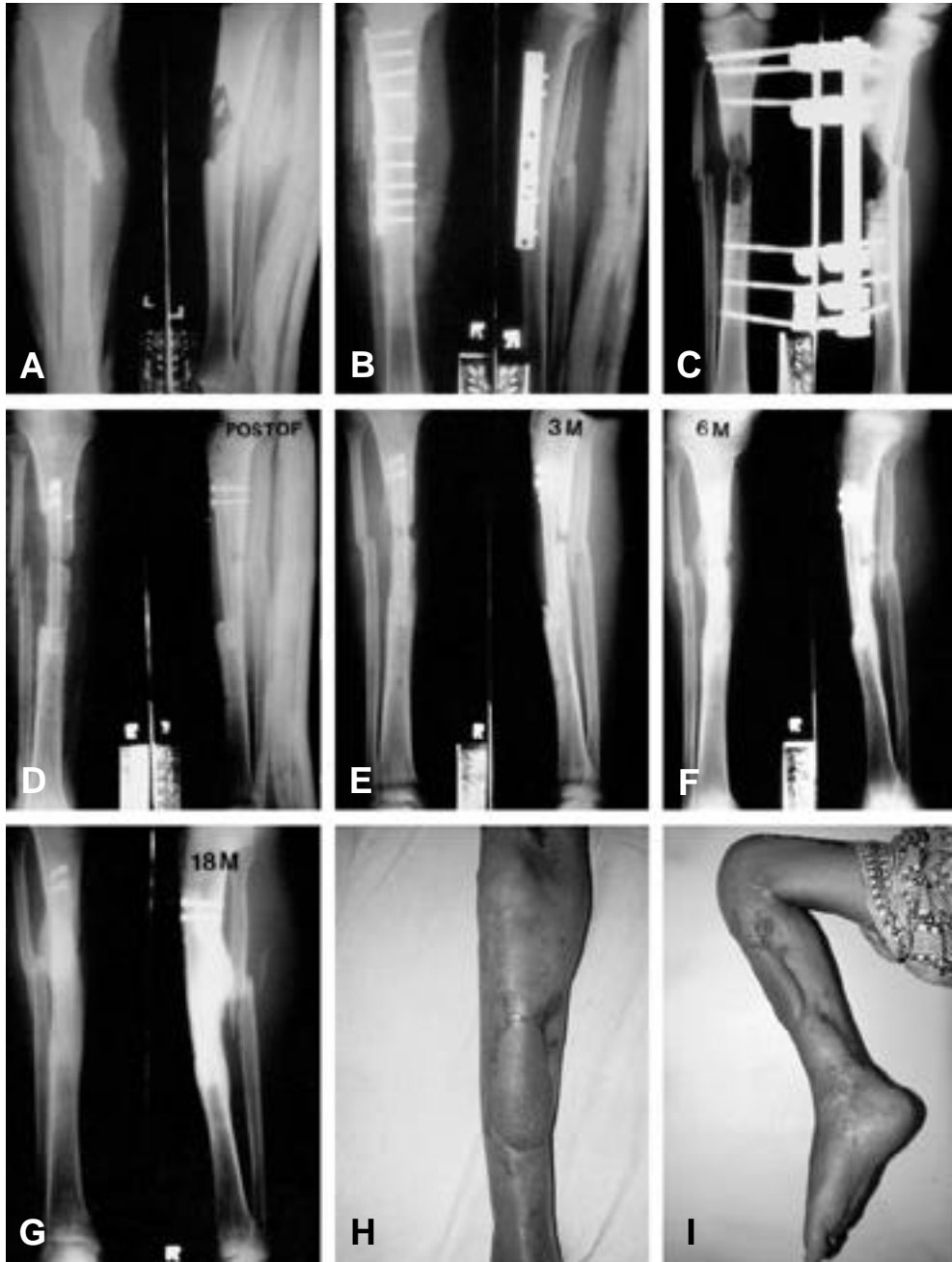

Fig. 2.

2

25

1/3

10cm x 5cm

(Pseudomonas

aeruginosa)

3

Enterobacter

, 5

cloacae Pseudomonas aeruginosa가

Papineau

17cm

가

, 1

14cm x 6cm

6

11.5cm

1

가

(flap)

4

5

가

가

9

3

3

53

4

5

, 7

2

10

(synostosis)

12.5cm

2

5

45

, 3

2

6

9

21cm

18cm x 7.5cm

4

19

1/3

6

Ilizarov  
flap)

(rotational skin

, 12

6  
33  
2  
5  
15cm x 5.5cm  
18.5cm  
6  
Freeland<sup>6)</sup> Jones<sup>7)</sup>  
Wallance<sup>8)</sup>  
50%  
39%  
6  
Onlay Graft, Inlay Graft,  
Barrel-Stave Graft, Dual Onlay Graft  
Massive Sliding Graft  
(creeping substitution)  
가  
18)  
1971 Strauch<sup>11)</sup>  
1974 Ostrup Fredric  
kson<sup>10)</sup>  
1975 Taylor<sup>12)</sup>  
17.5cm  
14.5cm x 6cm

:

20%

2)

가

가

6cm

3

1)

4

cm

11.5cm

21cm

20%

가

15)

17)

18.5cm x 7.5cm

O'Brien<sup>9)</sup>

가

가

14)

가

, 22~26cm

(intramedullary insertion) 가

가

가

5,13,15)

Croke<sup>4)</sup>

가

3~5

1.8~2.5mm,

2~4mm

cm

4~5

가

13)

가

12)

가

, Chen Yan<sup>3)</sup>

0.5~1cm

가

3)

Weiland<sup>17)</sup>

6cm

0.5~1cm

가

2

가

가

1983 Chen Yan<sup>3)</sup>

20cm

가 가

kinking twisting

20cm x 10cm

**Table 1.** Vascularized Osteocutaneous Free Flap with Fibula

| Case | Age /Sex | Injury site | Length of defect(cm) | Length of graft(cm) | Dimension of flap(cm <sup>2</sup> ) | Time to union (mon) | Time to bony hypertrophy (mon) |
|------|----------|-------------|----------------------|---------------------|-------------------------------------|---------------------|--------------------------------|
| 1    | 27/M     | mid. 1/3    | 10.5                 | 16.5                | 13.0 × 6.5                          | 4                   | 8                              |
| 2    | 25/M     | prox. 1/3   | 12.5                 | 17.0                | 14.0 × 6.0                          | 5                   | 9                              |
| 3    | 55/M     | mid. 1/     | 12.5                 | 15.0                | STSG                                | 6                   | 12                             |
| 4    | 19/M     | prox. 1/3   | 7.0                  | 11.5                | STSG                                | 5                   | 10                             |
| 5    | 45/M     | mid. 1/3    | 17.0                 | 21.0                | 18.0 × 7.5                          | 6                   | 12                             |
| 6    | 33/M     | mid. 1/3    | 15.0                 | 18.0                | 15.0 × 5.5                          | 5                   | 11                             |
| 7    | 47/M     | prox. 1/3   | 14.5                 | 17.5                | 14.5 × 6.0                          | 6                   | 12                             |

monitor  
가 , 가

3)

2 , 1 , 7 5

1 가

1981 Weiland<sup>8)</sup> (compact bone) 가 2 가 3 가 가 11.5cm 5 21cm 16.6cm 2 5 14.9cm × 6.3cm 10 6 가 가 12 (Table 1). 5 50 2 30 가 3 20 2 50 가 4 6 가 5.3 2 5



## REFERENCES

- 1) , , : ,18-6 : 1185-1192, 1983.
- 2) , , , : , 17-3 : 403-413,1982.
- 3) Chen, ZW. and Yan, W : *The study and clinical application of the Osteocutaneous flap of fibula. Microsurgery, 4:11-16, 1983*
- 4) Croke, HV : *The blood supply of the lower limb bones in men. Edingburgh and London : E & S Livingstone Ltd.*
- 5) Daniel, RK, and Terzis, JK : *Free tissue transfer by microvascular anastomosis. Reconstructive micro - surgery, Little, Brown and Co.191-280, 1977.*
- 6) Freeland, AE. and Muts, SB : *Posterior bone graft - ing for infected ununited fracture of the tibia. J. Bone and Joint Surg., 58-A:653-657, 1976.*
- 7) Jones, KG : *Treatment of infected nonunion of the tibia through the posterolateral approach. Clin. Orthop., 43:103-109, 1965.*
- 8) Lottes, JO : *Medullary nailing of tibia. Paper pre - sented at the Annual meeting of the American Academy of Orthopaedic Surgeons, Miami Beach, Florida, 24, 1963.*
- 9) O'Brien, BM, Haw, CS. and Kurata, T : *The micro - surgical revascularization of resected segments of tibia in the dog. J. Bone and Joint Surg., Vol. 60 B:266-270, 1978.*
- 10) Ostrup, LT. and Fredrickson, JM : *Distant transfer of a free living bone graft by microvascular anasto - mosis. Plast. and Reconstr. Surg., Vol. 54, No. 3:274-285, 1974.*
- 11) Strauch, B, Bloomberg, AE. and Levin, ML : *An experimental approach to mandibular replacement : island vascular composite rib graft. Brit. J. Plast. Surg., 24:334, 1971.*
- 12) Taylor, GI, Miller, GD. H. and Ham, FJ : *The free vascularized bone graft. Plast. and Reconstr. Surg. Vol.55:533-544, 1975.*
- 13) Taylor, GI : *Microvascular free bone transfer. Orthopaedic Clinics of North America, Vol.8:425-447, April, 1977.*
- 14) Taylor, GI, Bunke, HG. and Murray, W : *Vascularized osseous transplantation for reconstruc - tion of the tibia, Microsurgical composite tissue transplantation. The C.V. Mosby Co., 713-749, 1979.*

- 15) Taylor, GI : *Fibular transplantation, Microsurgical composite tissue transplantation. The C.V. Mosby Co., 713-749, 1979.*
- 16) Wallace, P : *Treatment of fractures with long-standing osteomyelitis. Arch. Surg., 61:379-386, 1954.*
- 17) Weiland, AJ. and Daniel, RK : *Microvascular anastomosis for bone grafts in the treatment of massive defects in bone, J. Bone and Joint surg., 61-A:98-104, 1979.*
- 18) Weiland, AJ : *Current concepts review. Vascularized free bone transplants. J. Bone and Joint Surg., Vol.63 A, No.1:166-169, 1981.*