

Case Report



Multiple Cerebral Hemorrhages Caused by Paradoxical Reperfusion Injury After Cranioplasty

Hyuk-Jin Oh , Jai-Joon Shim , Jae-Min Ahn , Jae-Sang Oh , and Seok-Mann Yoon

Department of Neurosurgery, Soonchunhyang University Cheonan Hospital, Cheonan, Korea

OPEN ACCESS

Received: Feb 24, 2022
Revised: Mar 21, 2022
Accepted: Apr 14, 2022
Published online: May 31, 2022

Address for correspondence:

Jae-Joon Shim
Department of Neurosurgery, Soonchunhyang University Cheonan Hospital, 31 Suncheonhyang 6-gil, Dongnam-gu, Cheonan 31151, Korea.
Email: funnylife@schmc.ac.kr

Copyright © 2022 Korean Neurotraumatology Society

This is an Open Access article distributed under the terms of the Creative Commons Attribution Non-Commercial License (<https://creativecommons.org/licenses/by-nc/4.0/>) which permits unrestricted non-commercial use, distribution, and reproduction in any medium, provided the original work is properly cited.

ORCID iDs

Hyuk-Jin Oh
<https://orcid.org/0000-0001-7189-1267>
Jai-Joon Shim
<https://orcid.org/0000-0002-1757-0611>
Jae-Min Ahn
<https://orcid.org/0000-0002-3427-8807>
Jae-Sang Oh
<https://orcid.org/0000-0003-4570-6763>
Seok-Mann Yoon
<https://orcid.org/0000-0002-0048-6309>

Funding

This work was supported by the Soonchunhyang University Research Fund.

Conflict of Interest

The authors have no financial conflicts of interest.

<https://kjnt.org>

ABSTRACT

Cranioplasty-related reperfusion injury has rarely been reported. Although there are several hypotheses, particularly regarding the mechanisms of the event, clear evidence is lacking. Here, we report the case of an 84-year-old man with traumatic intracranial hemorrhage and subdural hematoma who underwent decompressive craniectomy and hematoma evacuation in the right hemisphere. After 45 days, cranioplasty was performed using titanium. A preoperative perfusion study with 99m-Tc-HMPAO brain single-photon emission tomography revealed diffuse hypoperfusion in the left cerebral hemisphere with decreased vascular reserve. After cranioplasty, multiple cerebral hemorrhages were observed on immediate postoperative computed tomography. Cerebral hemorrhage eventually improved without surgery. Here, we report a case with findings revealed through perfusion studies before and after surgery.

Keywords: Decompressive craniectomy; Reperfusion injury; Traumatic intracranial hemorrhage; Technetium Tc 99m exametazime

INTRODUCTION

Reperfusion injury after cranioplasty is rare complication is a rare complication with high morbidity and mortality. The cause of reperfusion injury remains unknown, and hypotheses are being suggested. We experienced multiple cerebral hemorrhages due to reperfusion injury that occurred after cranioplasty, and we report a case through preoperative and postoperative perfusion imaging that can explain the cerebral blood flow dynamics.

CASE REPORT

An 84-year-old male was admitted to neurosurgical department with headache after slip down. A brain computed tomography (CT) and CT angiography presented a traumatic subarachnoid hemorrhage and subdural hemorrhage (SDH) without vascular abnormality. There was no significant change in follow-up CT at 8 hours after trauma, but the patient consciousness decreased to stupor stage with Left motor weakness 16 hours after trauma. Large amount of traumatic intracranial hemorrhage (ICH) was newly noticed on the CT and the amount of SDH increased (**FIGURE 1A-C**).

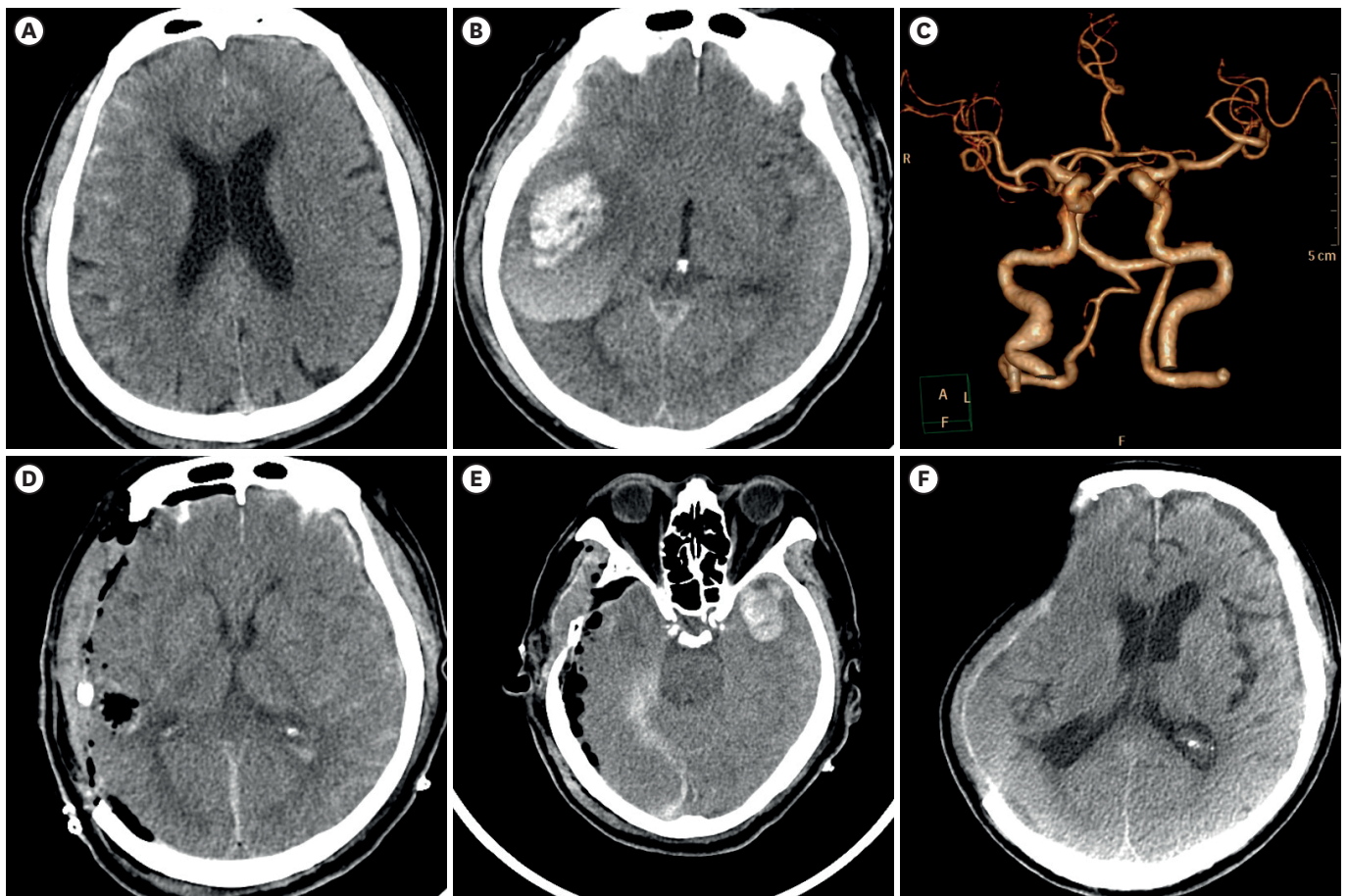


FIGURE 1. Brain CT scan on admission (A), after 16 hours later (B). CT angiography on admission (C) Postoperative CT showed ipsilateral decompressive craniectomy was done (D) and newly developed intracranial hemorrhage on the contralateral hemisphere (E). Brain CT confirmed the ipsilateral hemisphere was pressed by atmospheric pressure before cranioplasty (F). CT: computed tomography.

The emergent operation was performed by evacuating acute traumatic SDH and ICH with decompressive craniectomy (DC) on the right fronto-temporo-parietal cranial bone (**FIGURE 1D & E**). The patient recovered partially to drowsy consciousness after one month. Cranioplasty was performed with titanium using 3D printing technique on the 42nd day after the first operation. Diffuse Hypoperfusion in the left cerebral hemisphere with a decreased vascular reserve and perfusion defect in the right temporal lobe was identified in brain single-photon emission tomography (SPECT) conducted before surgery (**FIGURE 2A & B**). The operation was performed for 1 hour and 40 minutes, and there were no significant problems with blood pressure fluctuations or anesthesia depth maintenance during the operation. However, Multiple ICHs were observed in brain CT taken after surgery, and the patient's consciousness was decreased by stupor consciousness (**FIGURE 3A-C**). On the postoperative brain SPECT, hypoperfusion in the left cerebral hemisphere was recovered (**FIGURE 2C & D**). However, perfusion of the right cerebral hemisphere was rather reduced as a sequela of postoperative cerebral hemorrhages. Brain SPECT after 6 weeks revealed hyperperfusion in right cerebral hemisphere, hypoperfusion in left temporal lobe with decreased vascular reserve (**FIGURE 2E & F**). The neurological status of the patient was worse than before. Still, his consciousness was not improved to drowsy consciousness, and he recovered to a level where he could mumble, and he is undergoing continuous rehabilitation.

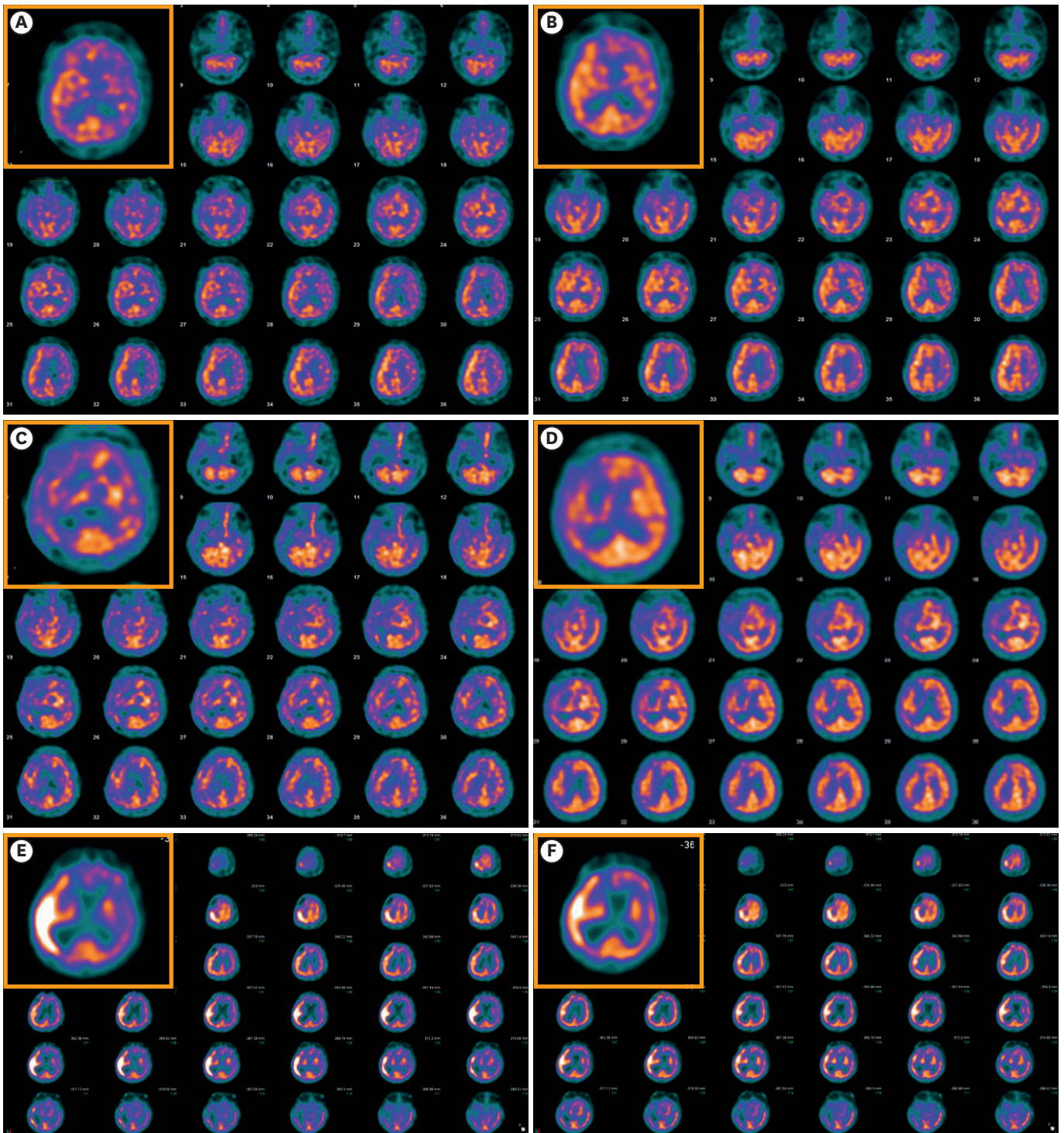


FIGURE 2. Brain single-photon emission tomography conducted before surgery (A & B), 7 days after cranioplasty (C & D), 6 weeks after cranioplasty (E & F). (A-B), (C-D), and (E-F) are pairs, respectively. (A-C-E) is the resting state, and (B-E-F) is the state after increasing the cerebral blood flow using acetazolamide (The key image is enlarged and marked in the yellow box).

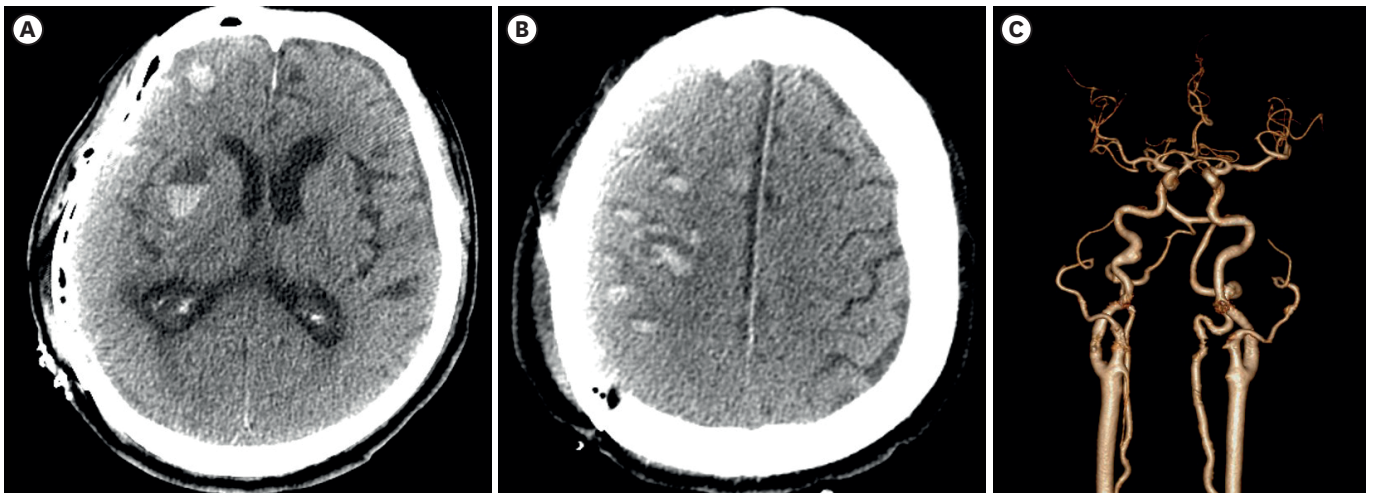


FIGURE 3. Brain computed tomography after cranioplasty (A-C). Multiple intracranial hemorrhage were confirmed without vascular abnormalities.

DISCUSSION

DC has been widely used as a surgical treatment to control intracranial hypertension. The purpose of this treatment method is to remove as appropriately sized skull bone to control brain tissue edema and prevent irreversible brain tissue damage. According to several reported literature, sequential cerebral blood flow changes appear after DC is performed.⁵⁾ The point is that CBF of the ipsilateral brain decreased after DC, but CBF recovers when cranioplasty is performed. After the increased intracranial hypertension is controlled by DC, the cerebral parenchyma is gradually compressed by atmospheric pressure. When this phenomenon progresses seriously, it is known as sinking skin flap syndrome (SSFS), which caused neurological deterioration.¹⁴⁾

In our patient, a decrease in blood flow, which is generally observed after DC, was not observed in the preoperative perfusion images, but rather increased CBF was observed. Preoperative CT Angiography was performed to find the cause of increased blood flow, but no accompanying vascular disease was observed.

Complications that can occur after cranioplasty are various, but about 20 cases with cerebral edema or hemorrhage without direct trauma during the surgical field have been reported so far^{1-4,6,41,13,15,16,18)} (**TABLE 1**). Kato et al.⁸⁾ analyzed the case series listed above and summarized several hypotheses. Venous stasis, reperfusion injury with autoregulation failure, microvascular displacement following rapid flow recovery, and suction drain with negative pressure may produce unexpected brain edema and hemorrhage. However, among the previously published literature, CBF of the preoperative ipsilateral brain was rarely increased, and most of them were reduced by atmospheric pressure.

The author suggested that this patient before surgery is thought to have a temporary congestion status with an increased ipsilateral blood volume due to an increase in CBF to withstand atmospheric pressure and relatively higher perfusion than the contralateral hemisphere. In this patient, it is estimated that cerebrovascular resistance decreases due to brain expansion after cranioplasty, resulting in increased cerebral perfusion pressure. After that, CBF, which has already increased, further increased as atmospheric pressure disappeared, resulting in

TABLE 1. Patients with intracerebral hemorrhage after cranioplasty reported in the literature

Reference	Age	Sex	Cause	Midline shift before CP	Time to CP (months)	Perfusion image	Type of implant	Outcome
Cecchi et al. (2008) ¹⁾	77	M	Infarction	+	2	-	Autologous	Expired
Eom et al. (2010) ³⁾	63	M	Infarction	+	10	-	Autologous	Expired
Chitale et al. (2013) ²⁾	64	M	Infarction	+	12	-	PEEK	Expired
Kwon et al. (2016) ⁹⁾	63	M	SAH	+	2	-	NR	NR
Missori et al. (2018) ²⁰⁾	54	M	Infarction	-	3	-	Autologous	Expired
Xiao (2020) ¹⁷⁾	29	M	TBI	-	4	-	Titanium	NR
Present study (2022)	84	M	TBI	-	1.5	+	Titanium	MCS

Patients with symptomatic internal carotid artery compression with apoplexy reported in the literature.

CP: cranioplasty, M: male, MCS: minimally consciousness state, NR: not report, PEEK: polyetheretherketone, SAH: subarachnoid hemorrhage, TBI: traumatic brain injury.

reperfusion damage such as ICH. Brain perfusion pressure dropped due to additional damage to the damaged brain due to postoperative ICH, and CBF increased again immediately after 6 weeks after imaging, brain hemorrhage was absorbed and recovered.

When unexpected complications occur in cranioplasty, several of these factors may appear for sole or complex reasons. In many cases, the decisive cause cannot be identified, but recognizing these factors in advance can reduce problems that may occur after surgery. Therefore, physicians should be considered that reperfusion hemorrhages may occur following cranioplasty in patients.

CONCLUSION

This is a case of multiple postoperative cerebral hemorrhages in patients with paradoxical reperfusion. Until now, there have been reported cases of cerebral hemorrhage caused by postoperative reperfusion, but it has rarely presented cerebral perfusion images, especially paradoxical changes before and after surgery. Postoperative hemorrhage after cranioplasty is a dramatic and unpredictable event. To prepare for complications that may occur before surgery, an overall evaluation of cerebral perfusion status in patients undergoing DC is necessary, and prior notice must be made in the informed consent before surgery.

REFERENCES

1. Cecchi PC, Rizzo P, Campello M, Schwarz A. Haemorrhagic infarction after autologous cranioplasty in a patient with sinking flap syndrome. *Acta Neurochir (Wien)* 150:409-410, 2008
[PUBMED](#) | [CROSSREF](#)
2. Chitale R, Tjoumakaris S, Gonzalez F, Dumont AS, Rosenwasser RH, Jabbour P. Infratentorial and supratentorial strokes after a cranioplasty. *Neurologist* 19:17-21, 2013
[PUBMED](#) | [CROSSREF](#)
3. Eom KS, Kim DW, Kang SD. Bilateral diffuse intracerebral hemorrhagic infarction after cranioplasty with autologous bone graft. *Clin Neurol Neurosurg* 112:336-340, 2010
[PUBMED](#) | [CROSSREF](#)
4. Evins AI, Boeris D, Burrell JC, Ducati A. Postoperative intracranial hypotension-associated venous congestion: case report and literature review. *Clin Neurol Neurosurg* 115:2243-2246, 2013
[PUBMED](#) | [CROSSREF](#)
5. Halani SH, Chu JK, Malcolm JG, Rindler RS, Allen JW, Grossberg JA, et al. Effects of cranioplasty on cerebral blood flow following decompressive craniectomy: a systematic review of the literature. *Neurosurgery* 81:204-216, 2017
[PUBMED](#) | [CROSSREF](#)

6. Hettige S, Norris JS. Mortality after local allergic response to titanium cranioplasty. *Acta Neurochir (Wien)* 154:1725-1726, 2012
[PUBMED](#) | [CROSSREF](#)
7. Honeybul S. Sudden death following cranioplasty: a complication of decompressive craniectomy for head injury. *Br J Neurosurg* 25:343-345, 2011
[PUBMED](#) | [CROSSREF](#)
8. Kato A, Morishima H, Nagashima G. Unexpected complications immediately after cranioplasty. *Acute Med Surg* 4:316-321, 2017
[PUBMED](#) | [CROSSREF](#)
9. Kwon SM, Cheong JH, Kim JM, Kim CH. Reperfusion injury after autologous cranioplasty in a patient with sinking skin flap syndrome. *J Korean Neurosurg Soc* 51:117-119, 2012
[PUBMED](#) | [CROSSREF](#)
10. Lee GS, Park SQ, Kim R, Cho SJ. Unexpected severe cerebral edema after cranioplasty: case report and literature review. *J Korean Neurosurg Soc* 58:76-78, 2015
[PUBMED](#) | [CROSSREF](#)
11. Mangubat E, Sani S. Acute global ischemic stroke after cranioplasty: case report and review of the literature. *Neurologist* 19:135-139, 2015
[PUBMED](#) | [CROSSREF](#)
12. Missori P, Currà A, Peschillo S, Fattapposta F, Toni D. Intracerebral hemorrhage after cranioplasty: an unpredictable treacherous complication due to reperfusion or possible systemic inflammatory response syndrome. *Neurol Sci* 39:959-960, 2018
[PUBMED](#) | [CROSSREF](#)
13. Santana-Cabrera L, Pérez-Ortiz C, Rodríguez-Escot C, Sánchez-Palacios M. Massive postoperative cerebral swelling following cranioplasty. *Int J Crit Illn Inj Sci* 2:107-108, 2012
[PUBMED](#) | [CROSSREF](#)
14. Sarov M, Guichard JP, Chibarro S, Guettard E, Godin O, Yelnik A, et al. Sinking skin flap syndrome and paradoxical herniation after hemicraniectomy for malignant hemispheric infarction. *Stroke* 41:560-562, 2010
[PUBMED](#) | [CROSSREF](#)
15. Sviri GE. Massive cerebral swelling immediately after cranioplasty, a fatal and unpredictable complication: report of 4 cases. *J Neurosurg* 123:1188-1193, 2015
[PUBMED](#) | [CROSSREF](#)
16. Van Roost D, Thees C, Brenke C, Oppel F, Winkler PA, Schramm J. Pseudohypoxic brain swelling: a newly defined complication after uneventful brain surgery, probably related to suction drainage. *Neurosurgery* 53:1315-1326, 2003
[PUBMED](#) | [CROSSREF](#)
17. Xiao Z. One case report of delayed severe intracerebral and intraventricular hemorrhage after cranioplasty. *Br J Neurosurg*, Forthcoming 2020
[PUBMED](#) | [CROSSREF](#)
18. Zebian B, Critchley G. Sudden death following cranioplasty: a complication of decompressive craniectomy for head injury. *Br J Neurosurg* 25:785-786, 2011
[PUBMED](#) | [CROSSREF](#)