



## 천공지를 이용한 피판술을 통한 회음부 괴저로 인한 결손부위의 재건

홍석원<sup>1</sup> · 최환준<sup>1,2</sup> · 김준혁<sup>1</sup>

<sup>1</sup>순천향대학교 의과대학 성형외과학교실, <sup>2</sup>순천향대학교 조직재생연구소

# Medial Femoral Circumflex Artery Perforator Based Fasciocutaneous Flap Aided in Healing of Scrotal Defect due to Fournier Gangrene

Seok Won Hong<sup>1</sup>, Hwan Jun Choi<sup>1,2</sup>, Jun Hyuk Kim<sup>1</sup>

<sup>1</sup>Department of Plastic and Reconstructive Surgery, Soonchunhyang University College of Medicine, Cheonan, Korea

<sup>2</sup>Institute of Tissue Regeneration, Soonchunhyang University, Cheonan, Korea

Fournier's gangrene is a rare, highly infectious necrotizing fasciitis of the perineum and genital area which is caused by a mixture of various bacterial organism. Treatment is predominantly surgical, including extensive and early drainage and debridement, considering negative-pressure wound therapy for helping to heal the wounds and broad-spectrum intravenous antibiotics therapy. Some reports have described the use of negative-pressure wound therapy combined with split thickness skin graft in the defect area. While, other recent reports suggest that local flap coverage rather than skin graft for reconstruction of perineal area. This study aims to suggest the use of medial femoral circumflex artery perforator based thigh flap for scrotal and perineal reconstruction in open areas secondary to the surgical debridement and negative-pressure wound therapy of Fournier's gangrene.

**Key Words:** Necrotizing fasciitis, Perforator flap, Fournier gangrene, Perineum

Perineal necrotizing fasciitis was first described in 1883<sup>1</sup>. It has high risk of morbidity and mortality. This lethal disease, also called Fournier's gangrene (FG), is a rare, infectious necrotizing fasciitis of external genitalia, perineal or perianal regions, with or without involvement of the underlying muscle<sup>2</sup>. The disease has a higher incidence in males and skin loss in the scrotal and perineal region is very common. Treatment is predominantly surgical, including extensive and early drainage and de-

bridement, considering negative-pressure wound therapy (NPWT) for helping to heal the wounds and broad-spectrum intravenous antibiotics therapy. Some reports have described the use of NPWT combined with split thickness skin graft in the defect area<sup>3</sup>. While, other recent reports suggest that local flap coverage rather than skin graft for reconstruction of perineal area. Perineal or scrotal reconstruction should consider the esthetic and physiological characteristics, as much as possible. The ideal

Received February 7, 2019, Revised [1] July 9, 2019, [2] July 20, 2019, Accepted August 12, 2019

Corresponding author: Hwan Jun Choi

Department of Plastic and Reconstructive Surgery, Soonchunhyang University Cheonan Hospital, 31 Sooncheonhyang 6-gil, Dongnam-gu, Cheonan 31151, Korea

TEL: +82-41-570-2195, FAX: +82-41-574-6133, E-mail: medi619@hanmail.net, ORCID: <https://orcid.org/0000-0002-0752-0389>

Copyright © 2019 by Korean Society for Surgery of the Hand, Korean Society for Microsurgery, and Korean Society for Surgery of the Peripheral Nerve. All Rights reserved. This is an Open Access article distributed under the terms of the Creative Commons Attribution Non-Commercial License (<http://creativecommons.org/licenses/by-nc/4.0/>) which permits unrestricted non-commercial use, distribution, and reproduction in any medium, provided the original work is properly cited.

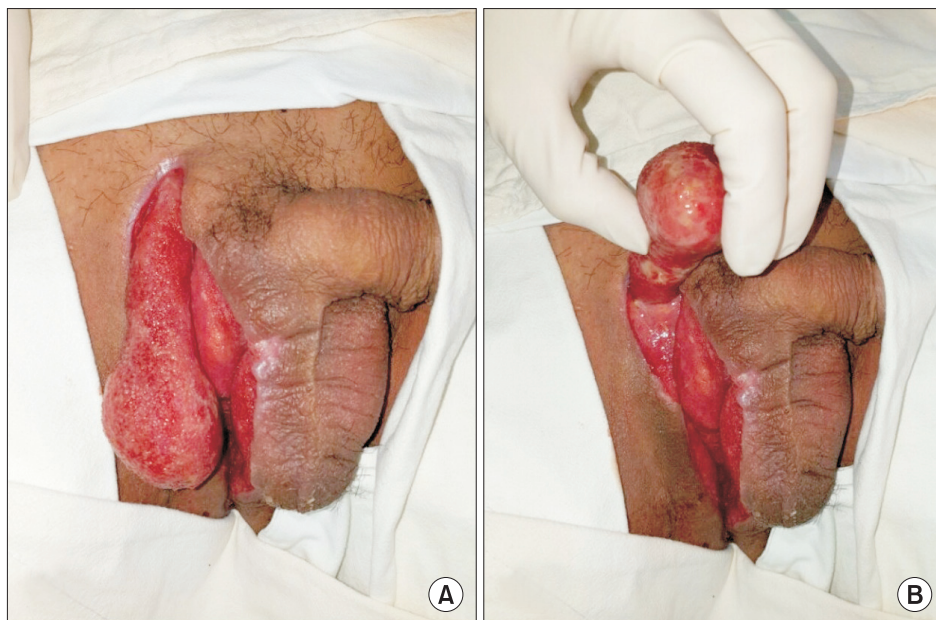
procedures for reconstruction include stability resistant to traction force, movements which patient's motion make, and adequate volume to cover the defect area with minimal sequelae to the donor site. Moreover, surgeons must consider the thermoregulation of the testicles<sup>4,5</sup>. Several procedures have been suggested, and there is not a single one that can be considered ideal applicable to all cases. The choice of technique depends on factors association with patient's characteristics, features of defect, such as size and location<sup>2,4,5</sup>.

This study aims to suggest the use of medial femoral circumflex artery perforator based fasciocutaneous thigh flap for scrotal and perineal reconstruction in open areas secondary to the surgical debridement and NPWT of FG.

## CASE REPORT

A 48-year-old male patient who has diabetic mellitus presented with a progressively unexplained heating sensation, scrotal ache and swelling. He came to the local hospital after onset to diagnosis and treat. During outpatient treatment, a suspected diagnosis of scrotitis was made, and the patient felt worse. However, despite the treatment, the skin of the scrotum continued to necrotized, and he was transferred to our department, immediately. Physical examination showed a right scrotal

skin defect, extensive right inguinal region defects and purulent necrotizing tissue covering, which was accompanied by swelling and erythema of the surrounding skin. Right unilateral testis was exposed. The patient remained afebrile with stable vital signs. Full blood count, an erythrocyte sedimentation rate (ESR) count and a wound microbiology swab were taken. Blood chemistry showed a white blood cell count of  $15.6 \times 10^9/L$  and an ESR of 63 mm/h. Cultures of the exudates from the scrotal wound grew *Klebsiella pneumoniae*. The patient had no history of dysuria or hematuria. His past surgical history was unremarkable. Because the patient's condition had worse, immediate surgical debridement was necessary. We performed not only daily operative wound irrigation and debridement but also adequate intravenous ciprofloxacin 400 mg twice a day which was adjusted according to the drug sensitivity results until the end of the treatment. Patient was foley catheter applied state. When the wound bed covered with somewhat healthy granulation tissue without infection signs such as turbid discharge and induration, we applied vacuum machine for NPWT to secure the wound from fecal contamination and prepare the wound bed. Twice a week for a total of three weeks, we performed changing vacuum machine and surgical debridement, if necessary. During this time, the patient did not complain of any pain or bleeding, which are common

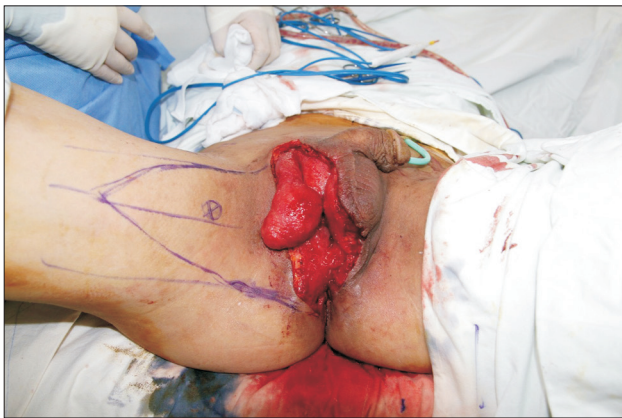

**Fig. 1.** A 48-year-old male with scrotal and perineal defects due to Fournier's gangrene. (A) Post-operative periods: 21 days of debridement and negative-pressure wound therapy (B) right unilateral testis totally was exposed.

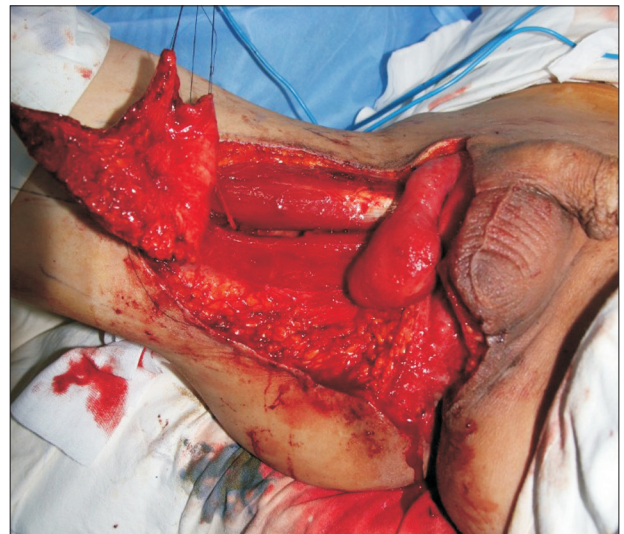complications of NPWT. When the wound bed had been covered with healthy granulation tissue without debritic tissue (Fig. 1), scrotal reconstruction with medical femoral circumflex artery (MFCA) perforator based fasciocutaneous V-Y advancement flap under general anesthesia was performed.

To perform the MFCA perforator based flap, the patient was positioned in the lithotomy position. Using handheld Doppler, we found and marked blue circle meaning the perforator of MFCA and designed V-Y pattern flap demarcation (Fig. 2). Resection of fibrotic-scar tissue and excessive granulation tissue was performed in the entire affected region—Perineum, testes and funiculi. A V-Y pattern advancement flap of the superomedial region of

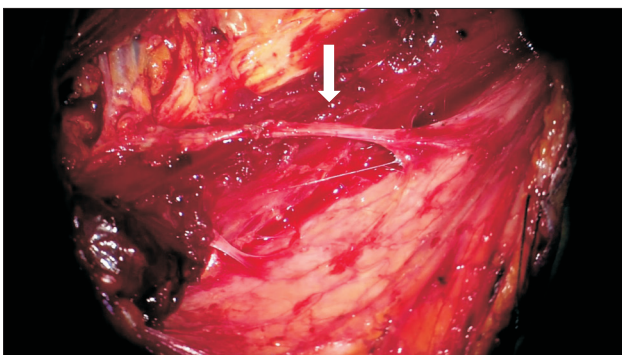
the thigh was used, with dissection in the fasciocutaneous plane and evidencing the gracilis muscle throughout the bed, without direct handling. Under using microscope, the perforator of MFCA to skin flap which runs deep between the adductor magnus and longus was found and preserved (Fig. 3, 4). The patency of the vessel was well. After flap inset, two hemovac were inserted and flap was repair with No.4-0 Nylon. The donor area was submitted to primary closure, by planes. Ten days postoperatively, the patient experienced no complication within adequate functional and aesthetic results (Fig. 5).



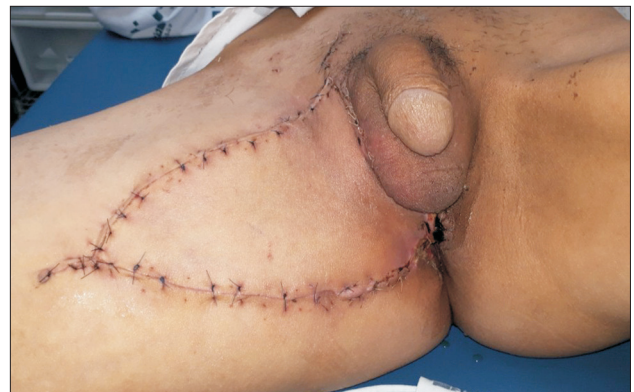**Fig. 2.** A 48-year-old male with scrotal and perineal defects due to Fournier's gangrene. Using handheld Doppler, we marked the blue circle meaning the perforator of medial femoral circumflex artery and designed V-Y pattern fasciocutaneous flap for reconstruction.



**Fig. 4.** Dissected and mobilized flap. Medical femoral circumflex artery perforator preserved V-Y pattern fasciocutaneous flap was elevated without direct muscle handling.



**Fig. 3.** Under microscope, the perforator of medial femoral circumflex artery to skin flap which runs deep between the adductor magnus and longus was found and preserved.



**Fig. 5.** Postoperative images after 12 days. There was no complication within adequate functional and aesthetic results.

## DISCUSSION

FG is a rare, highly infectious necrotizing fasciitis of the perineum and genital area which is caused by a mixture of various bacterial organism<sup>2,6</sup>. For several reasons, when the organisms appear to spread into the subcutaneous tissue, they produce fascial necrosis with and obliterative endarteritis leading to further tissue necrosis with or without the involvement of underlying muscle<sup>7,8</sup>. The mortality rate from this infection ranges from 0 to 67%<sup>9</sup>. Extensive surgical debridement under early recognition or diagnosis is crucial step to FG.

In a retrospective analysis of 72 patients with FG, Kabay et al.<sup>10</sup> highlighted that a time delay in surgical debridement was associated with significant mortality. Because the initial surgical debridement, with adequate resection of the necrotic or non-viable tissues, is considered the most important factor for survival<sup>11</sup>, there must be checked the degree and depth of the infection or necrosis as early as possible. Resection of the deep fascia and underlying muscle is not usually necessary and these structures are rarely involved in the disease process.

Our study considers the need for additional care for the adaptation of the adhesive films to the perineal contours and the adequate isolation of the perianal region as important. Negative pressure wound therapy is a great option in the wound preparation phase after complete debridement of the necrotic tissues<sup>12</sup>.

Within resulting in large scrotal, perineal and abdominal defects by progressive process underlying FG, there are several reports for reconstruction. The important choice of surgical reconstruction is based on the characteristics of the defect, such as size, location and depth as well as the availability of local tissue<sup>5</sup>. The following are technical options for reconstruction that have all been described in the literature: (1) primary closure, (2) split-thickness skin grafts, (3) local skin flap, (4) fasciocutaneous perforator flaps, (5) myocutaneous flaps.

In general, primary closure of the wound provides the best functional and cosmetic results but is only useful in small to medium sized lesions.

Partial split-thickness skin grafting within primary

repair or total split-thickness skin grafting is suggested by several reports, such as Tan et al.<sup>13</sup> and Maguiña et al.<sup>14</sup> They informed both the efficiency and effectiveness of split-thickness skin grafts by the reduction in recovery time and excellent functional and aesthetic results. Careful care is needed to fix the grafts and the tunica vaginalis should be present with favorable granulation tissue. While, there is a high danger of skin loss due to hematoma, shearing force with patient's tiny movement. It can't provide the volume fully to the scrotal defect area which is extremely sensitive. Some studies reported cases of graft contracture and undesirable cosmetic results<sup>5,12,13</sup>.

Various fasciocutaneous flaps have been used for perineal and scrotal reconstruction. These flaps can provide a sufficient surface coverage than skin grafts. Many literatures also report superior functional and cosmetic outcomes compared to skin grafts, possibly due to the reduced incidence of skin contracture<sup>15</sup>. They suggest that fasciocutaneous flap can provide much aesthetic outcomes with less skin contracture and enough volume to protect the scrotal area<sup>15</sup>. Hirshowitz et al.<sup>16</sup> initially described the use of superomedial fasciocutaneous thigh flap as a "probably" arterial flap using a different demarcation, following the medial thigh curvature.

Although one can consider the limitation of the cross-sectional diameter and the skin elasticity of the medial thigh region as a disadvantage, MFCA perforator based fasciocutaneous flap has more advantage of having a reliable blood supply, minimal donor site morbidity and preservation of the underlying muscle<sup>17</sup>. Then the reconstruction can be performed in a single stage without changing the patient's position on the surgical table.

In conclusion, there are various technique to reconstruct the scrotal and perineal defect area as we mentioned above. Skin grafts may be a good choice of reconstruction. However, there are several risk of skin loss and complication. This MFCA perforator based fasciocutaneous flap also has disadvantages such as longer time operation which burden to the patient's general condition and donor site morbidity. But, in the long term perspective, skin grafts do not show any advantage over the perforator flap in cosmetic and functional aspects. MFCA perfora-

tor based fasciocutaneous flap is a reliable and versatile option for the reconstruction of scrotal and perineal areas due to FG, showing excellent functional and cosmetic outcomes without complication such as significant sequelae to the donor site.

## CONFLICTS OF INTEREST

The authors have nothing to disclose.

## ACKNOWLEDGEMENTS

This work was supported by the Soonchunhyang University Research Fund.

## REFERENCES

1. Fournier JA. Jean-Alfred Fournier 1832-1914. *gangrène foudroyante de la verge (overwhelming gangrene)*. *Sem Med* 1883. *Dis Colon Rectum*. 1988;31:984-8.
2. Ozkan OF, Koksall N, Altinli E, et al. Fournier's gangrene current approaches. *Int Wound J*. 2016;13:713-6.
3. Tian Y, Liu T, Zhao CQ, Lei ZY, Fan DL, Mao TC. Negative pressure wound therapy and split thickness skin graft aided in the healing of extensive perineum necrotizing fasciitis without faecal diversion: a case report. *BMC Surg*. 2018;18:77.
4. Mopuri N, O'Connor EF, Iwuagwu FC. Scrotal reconstruction with modified pudendal thigh flaps. *J Plast Reconstr Aesthet Surg*. 2016;69:278-83.
5. Ferreira PC, Reis JC, Amarante JM, et al. Fournier's gangrene: a review of 43 reconstructive cases. *Plast Reconstr Surg*. 2007;119:175-84.
6. Yanar H, Taviloglu K, Ertekin C, et al. Fournier's gangrene: risk factors and strategies for management. *World J Surg*. 2006;30:1750-4.
7. Morpurgo E, Galandiuk S. Fournier's gangrene. *Surg Clin North Am*. 2002;82:1213-24.
8. Altarac S, Katušin D, Crnica S, Papeš D, Rajković Z, Arslani N. Fournier's gangrene: etiology and outcome analysis of 41 patients. *Urol Int*. 2012;88:289-93.
9. Ferreira MC, Tuma P Jr, Carvalho VF, Kamamoto F. Complex wounds. *Clinics (Sao Paulo)*. 2006;61:571-8.
10. Kabay S, Yucel M, Yaylak F, et al. The clinical features of Fournier's gangrene and the predictivity of the Fournier's gangrene severity index on the outcomes. *Int Urol Nephrol*. 2008;40:997-1004.
11. Thwaini A, Khan A, Malik A, et al. Fournier's gangrene and its emergency management. *Postgrad Med J*. 2006;82:516-9.
12. Chen SY, Fu JP, Chen TM, Chen SG. Reconstruction of scrotal and perineal defects in Fournier's gangrene. *J Plast Reconstr Aesthet Surg*. 2011;64:528-34.
13. Tan BK, Rasheed MZ, Wu WT. Scrotal reconstruction by testicular apposition and wrap-around skin grafting. *J Plast Reconstr Aesthet Surg*. 2011;64:944-8.
14. Maguiña P, Palmieri TL, Greenhalgh DG. Split thickness skin grafting for recreation of the scrotum following Fournier's gangrene. *Burns*. 2003;29:857-62.
15. Sinna R, Qassemayr Q, Benhaim T, et al. Perforator flaps: a new option in perineal reconstruction. *J Plast Reconstr Aesthet Surg*. 2010;63:e766-74.
16. Hirshowitz B, Moscona R, Kaufman T, Pnini A. One-stage reconstruction of the scrotum following Fournier's syndrome using a probable arterial flap. *Plast Reconstr Surg*. 1980;66:608-12.
17. Lee SH, Rah DK, Lee WJ. Penoscrotal reconstruction with gracilis muscle flap and internal pudendal artery perforator flap transposition. *Urology*. 2012;79:1390-4.

## 천공지를 이용한 피판술을 통한 회음부 괴저로 인한 결손부위의 재건

홍석원<sup>1</sup> · 최환준<sup>1,2</sup> · 김준혁<sup>1</sup>

<sup>1</sup>순천향대학교 의과대학 성형외과학교실, <sup>2</sup>순천향대학교 조직재생연구소

회음부 괴저는 회음부와 생식기 부위의 희귀한 매우 감염성 있는 괴사성 근막염이다. 치료는 우선적으로 조기의 광범위한 수술적 변연절제술 및 배액을 고려해야 하며 광범위 정맥 항생제 치료와 함께 상처 부위의 회복을 돕기 위한 음압 상처 치료를 고려해 볼 수 있다. 일부 연구에서는 결손 부위에 대하여 피부 이식 및 음압 상처 치료의 복합 치료가 효과적이라고 기술하였다. 반면 최근 다른 연구에서는 회음부 및 생식기 부위의 재건에 있어서 피부 이식보다 피판술이 기능적 및 미용적으로 좋다는 결과가 있었다. 본 연구에서는 회음부 괴저의 수술적 광범위 절제술 및 음압 치료 이후 회복되는 과정에서 발생한 생식기 및 회음부 결손의 재건 수술에 있어서 더욱 기능적 및 미용적으로 나은 결과를 가져오기 위해 내측대퇴회선동맥의 천공지를 이용한 근막피판술을 통한 재건을 진행하였고 이에 대하여 좋은 결과가 있어 보고하고자 한다.

**색인단어:** 괴사성 근막염, 천공지 피판, 회음부 괴저, 회음부

**접수일** 2019년 2월 7일 **수정일** 1차: 2019년 7월 9일, 2차: 2019년 7월 20일 **게재확정일** 2019년 8월 12일

**교신저자** 최환준

31151, 천안시 동남구 순천향6길 31, 순천향대학교 부속 천안병원 성형외과

**TEL** 041-570-2195 **FAX** 041-574-6133 **E-mail** medi619@hanmail.net

**ORCID** <https://orcid.org/0000-0002-0752-0389>