

CASE REPORT

Sarcomatoid carcinoma in the trachea: A case report and literature review

Si-Hyong Jang¹, Hyun D. Cho¹, Ji-Hye Lee¹, Hyun J. Lee¹, Soon A. Hong¹, Junhun Cho¹, Ho S. Lee² & Mee-Hye Oh¹

1 Department of Pathology, College of Medicine, Soonchunhyang University Cheonan Hospital, Cheonan, South Korea

2 Department of Internal Medicine, College of Medicine, Soonchunhyang University Cheonan Hospital, Cheonan, South Korea

Keywords

Sarcomatoid carcinoma; spindle cell carcinoma; trachea.

Correspondence

Mee-Hye Oh, Department of Pathology, Soonchunhyang University Cheonan Hospital, 31, Soonchunhyang 6 Gil, Dongnam-gu, Cheonan 330-721, South Korea.
Tel: +82 41 570 3582
Fax: +82 41 570 3580
Email: mhoh0212@hanmail.net

Received: 7 December 2016;

Accepted: 27 February 2017.

doi: 10.1111/1759-7714.12437

Thoracic Cancer 8 (2017) 278–282

Abstract

Tracheal sarcomatoid carcinoma is an extremely infrequent neoplasm with unclear pathogenesis and clinical outcomes. To date, only two cases have been described in English literature. We report a case of a 37-year-old patient complaining of hemoptysis, dyspnea, and cough. An intraluminal polypoid mass in the trachea was found and ultimately diagnosed as tracheal sarcomatoid carcinoma in the cervical trachea with both carcinomatous and sarcomatoid morphology. The patient is alive without recurrence after segmental resection of the trachea. We also present a comparative analysis of our case with a prior tracheal sarcomatoid carcinoma case.

Introduction

The trachea is a long tubal airway structure that extends from the lower border of the cricoid cartilage to the carina.¹ The trachea is relatively free from malignant tumor, with the prevalence of primary tracheal cancer ranging from 0.1% to 0.4% of all newly developed cancers. The most frequent cancer types occurring in the trachea could be listed in order as squamous cell carcinoma, adenoid cystic carcinoma, and neuroendocrine tumor. The prognosis of tracheal cancers mainly depends on the histologic subtype and extent of disease.²

Sarcomatoid carcinoma of the upper aerodigestive tract is a rare variant form of squamous cell carcinoma that is also described as spindle cell carcinoma, pleomorphic carcinoma, carcinosarcoma, pseudocarcinoma, and pseudosarcoma because the tumor exhibits characteristic morphology similar to that of partially or entirely mesenchymal-originated cells.³ In the head and neck, sarcomatoid carcinoma predominantly develops in the larynx, oral cavity, hypopharynx, and oropharynx.⁴ The trachea is

infrequently affected by sarcomatoid carcinoma. To date, only two cases of sarcomatoid carcinoma in the trachea have been reported in English literature.^{5,6}

We report an unusual case of sarcomatoid carcinoma arising in the trachea and present a literature review of the previous reported tracheal sarcomatoid carcinoma cases.

Case report

A 37-year-old man visited our ear, nose and throat outpatient department with symptoms of bloody sputum, cough, and foreign body sensation in the neck for the previous month. The patient had no relevant personal or medical history, and he was a non-smoker. He also complained of loss of appetite, weight loss of approximately 3 kg over three months, and mild dyspnea. His vital signs were stable. Auscultation revealed an intermittent wheezing sound in the lower neck area during coughing. Breathing in both of the lung fields was clear, and all laboratory test values, including tumor markers, were within the normal limits. Bronchoscopy revealed the presence of a soft, round

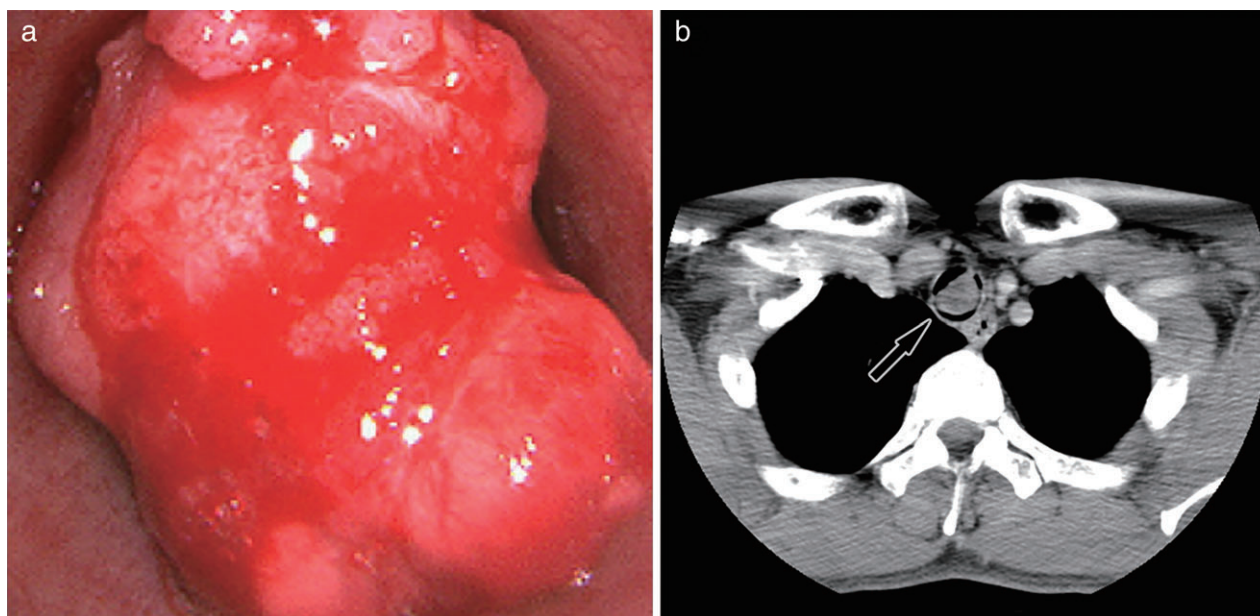


Figure 1 (a) Bronchoscopy revealed a polypoid protruding intraluminal mass in the trachea. (b) Chest computed tomography showed a round enhancing mass in the trachea but no evidence of invasion into adjacent tissue.

polypoid mass of approximately 2.0 cm in diameter that was partially obstructing the tracheal lumen (Fig 1a). Bronchoscopic biopsy was performed. The patient was discharged, but while waiting for his next outpatient appointment, tissue material was incidentally ejected during coughing. He revisited our emergency department and the ejected tissue was pathologically evaluated. Initial positron emission tomography and computed tomography scans demonstrated a relatively well circumscribed, enhancing, and hypermetabolic mass protruding within the tracheal lumen (Fig 1b). There was no evidence of metastatic lesion. Microscopic examination of the expectorated tissue and bronchoscopic biopsy showed a round-shaped hemorrhagic tumor accompanied by surface ulceration. The tumor was composed of both elongated spindle cells and round to polygonal epithelioid cells. The tumor consisted of moderate to severe pleomorphic cells with a moderate amount of cytoplasm and one or two prominent nucleoli. Mitotic activity was frequently found up to 10/10 HPFs. Immunohistochemistry revealed that the tumor was focal weak positive for epithelial membrane antigen (EMA) and vimentin in both polygonal and spindle cell areas. p63 staining showed immunoreactivity in the tumor cells (Fig 2). Smooth muscle actin, desmin, E-cadherin, cytokeratin (CK)5/6, p40, and CK AE1/AE3 were negative. Considering the histologic and immunohistochemical results, we diagnosed the tumor as sarcomatoid carcinoma. Segmental resection of the trachea was performed. The tumor was located 8 cm below the vocal cords. The length of the

resected segment was 3 cm. After confirming that the tumor was absent on both resection margins in frozen sections, end-to-end anastomosis was performed. On surgical specimen evaluation, the residual tumor size was 2.2 × 1.6 cm, and microscopic features were similar to those of the previously obtained expectorated tissue and bronchoscopic specimen. The tumor had invaded into the submucosal layer but not into the cartilage, and there was no evidence of lymphovascular invasion. After surgery, the patient received radiation therapy and six cycles of chemotherapy with docetaxel and carboplatin. The patient was regularly followed up using computed tomography, positron emission tomography, and ultrasound of the neck every six months, and he has been free from disease for five years after surgery.

Discussion

Primary tracheal tumors are uncommon, occupying 0.1–0.4% of all newly diagnosed malignancies. Malignant tumors in the trachea are mainly composed of squamous cell carcinoma and adenoid cystic carcinoma. The overall five-year survival of tracheal cancer is estimated at 27.1%. Squamous cell carcinoma and its subtypes have a poor prognosis.² Sarcomatoid carcinoma arising in the trachea is extremely infrequent, with only two cases reported to date.^{5,6} As a result, the clinical outcome of tracheal sarcomatoid carcinoma has not been investigated. Of the two reported cases, one patient who did not undergo surgery

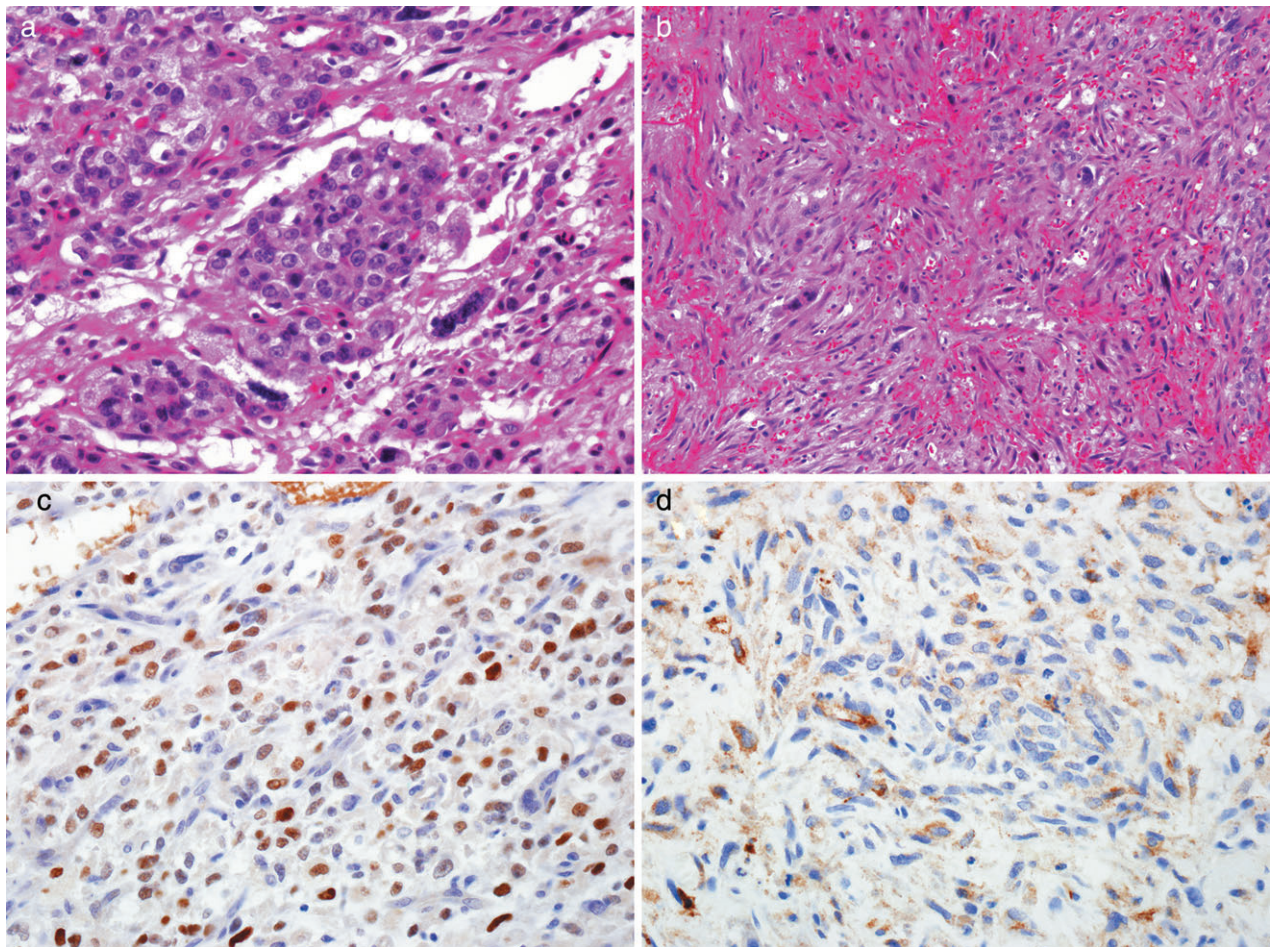


Figure 2 (a) The tumor displayed cohesive epithelioid cell nests that comprised round to polygonal pleomorphic cells (hematoxylin and eosin [H&E], 400 \times). (b) The tumor had sarcomatoid areas with atypical spindle cells (H&E, 400 \times). (c) Immunohistochemistry for p63 (epithelial marker) was positive in the nuclei of tumor cells (400 \times). (d) Immunohistochemistry for epithelial membrane antigen exhibited focal and weak positivity in the tumor cells (400 \times).

died five months after diagnosis, while the other who underwent resection survived. Complete resection and localization of the tracheal sarcomatoid carcinoma could contribute to a favorable outcome, as with other subtypes of tracheal tumors.

Sarcomatoid carcinoma in the upper aerodigestive tract is an uncommon neoplasm with the combined morphology of squamous cell carcinoma and a malignant spindle cell component; the tumor appears to have ambiguous and divergent pathogenesis.⁴ In head and neck cancers, spindle or mesenchymal-like cells could be derived from the epithelial component of squamous cell carcinoma via epithelial-mesenchymal transition.⁷ Based on chromosomal and mutation studies, mesenchymal-like elements of sarcomatoid carcinomas have recently been considered to originate from identical progenitor cells with epithelioid elements.⁸ The tumor cells characteristically display co-

expression of both epithelial markers, such as CK AE1/AE3, p63, p40, CK18, and EMA, and mesenchymal markers, such as vimentin, which can be helpful for confirming the presence of heterologous tumor components. Notably, p63 immunoreactivity in both epithelial and spindle cells can be the basis for a diagnosis of sarcomatoid carcinoma in the head and neck.⁷ Histologically, our case exhibited a cervical tracheal mass composed of both epithelioid and mesenchymal elements. Immunohistochemical results for epithelial (CK AE1/AE3, EMA, p40, CK5/6 and E-cadherin) and mesenchymal markers (vimentin) were also compatible with sarcomatoid carcinoma. Based on histology and immunohistochemistry findings, we ultimately diagnosed the tracheal tumor as sarcomatoid carcinoma.

Sarcomatoid carcinoma or carcinosarcoma in other organs usually presents with a poor prognosis because

Table 1 Summary of clinicopathological characteristics

	Aksu <i>et al.</i> ⁵	Gurria <i>et al.</i> ⁶	Present case
Age/gender	78/male	75/male	37/male
Symptom	Weight loss, cough, dyspnea, bloody sputum	Dyspnea, cough, wheezing	Weight loss, cough, dyspnea, bloody sputum, foreign body sensation
Personal history	Smoking history, asbestos exposure	Past smoking history	No smoking history
Location	Thoracic trachea	Cervical trachea	Cervical trachea
Tumor size (cm)	2	1.8	2.2
Gross	Endobronchial polypoid	Endobronchial polypoid	Endobronchial polypoid
Tumor invasion	No available data	No invasion into cartilage	No invasion into cartilage (submucosa)
Surgical margins	No surgery	Clear resection margins	Clear resection margins
Perineural invasion	Not described	No	No
Lymphovascular invasion	Not described	No	No
Treatment	Chemotherapy and radiation therapy	Surgery	Surgery, chemotherapy, and radiation therapy
Clinical outcome	Died of disease progression after five months	Alive without recurrence for six months	Alive without recurrence for five years

mesenchymal transition of epithelial tumors is associated with aggressive tumor properties.^{9,10} Pulmonary pleomorphic carcinoma is clearly defined as a non-small cell carcinoma that contains more than 10% spindle and/or giant cells or a carcinoma exclusively composed of spindle and giant cells.¹¹ Sarcomatoid carcinoma arising in the upper aerodigestive tract usually displays aggressive biologic behavior, but distinct diagnostic criteria are not yet available for the upper aerodigestive tract because of the rarity of this disease. We thought it necessary to collect and analyze clinicopathological information of sarcomatoid carcinoma cases in the head and neck in order to establish appropriate disease classification and, thus, accurately predict patient prognosis.

Sarcomatoid carcinoma that arises in the trachea is extremely rare. To the best of our knowledge, only two cases have previously been reported in English literature.^{5,6} The clinicopathological features of the previously reported cases and our case are summarized in Table 1. Our patient was a young man without any history of exposure to smoking or environmental carcinogens. The tumor was located at the cervical trachea and thus could be removed completely by surgery. He ultimately achieved a favorable outcome, with no evidence of recurrence or metastasis for five years. A comparison of the previous cases with our case indicates that complete surgical removal of the tumor could be an effective treatment modality.

Myofibroblastic tumor, inflammatory myofibroblastic tumor, leiomyosarcoma, synovial sarcoma, myoepithelial carcinoma, and malignant melanoma could be considered in differential diagnosis. Myofibroblastic tumor, inflammatory myofibroblastic tumor, and leiomyosarcoma are distinguished from sarcomatoid carcinoma based on the absence of epithelioid morphologic areas and the lack of immunoreactivity for epithelial markers.^{12,13} Malignant

melanoma occasionally exhibits biphasic phenotypes with malignant spindle cells. Immunohistochemical staining for HMB-45, S-100, and Melan-A are typically positive in melanoma, but negative for non-specific staining for epithelial and mesenchymal markers. Myoepithelial carcinoma has a characteristic immunoprofile of positive staining for epithelial markers (EMA) and negative staining for S-100 protein. Synovial sarcoma appears with either a monophasic or a biphasic pattern. Histologically, synovial sarcoma usually shows high cellularity, interlacing fascicular formation, hemangiopericytic arrangement, and focal myxoid stromal appearance.¹⁴

Herein, we reported a very rare case of tracheal sarcomatoid carcinoma with epithelioid and spindle cell histology, and reviewed the literature on sarcomatoid carcinoma in the trachea as well as the head and neck. It is necessary to create awareness about sarcomatoid or spindle cell morphology in the upper aerodigestive system to establish clinicopathological significance and set proper diagnostic criteria for sarcomatoid carcinoma in the head and neck.

Acknowledgment

This work was supported in part by the Soonchunhyang University Research Fund.

Disclosure

No authors report any conflict of interest.

References

- 1 Junker K. Pathology of tracheal tumors. *Thorac Surg Clin* 2014; **24**: 7–11.

- 2 Urdaneta AI, Yu JB, Wilson LD. Population based cancer registry analysis of primary tracheal carcinoma. *Am J Clin Oncol* 2011; **34**: 32–7.
- 3 Nappi O, Wick MR. Sarcomatoid neoplasms of the respiratory tract. *Semin Diagn Pathol* 1993; **10**: 137–47.
- 4 Ansari-Lari MA, Hoque MO, Califano J, Westra WH. Immunohistochemical p53 expression patterns in sarcomatoid carcinomas of the upper respiratory tract. *Am J Surg Pathol* 2002; **26**: 1024–31.
- 5 Aksu K, Aktas Z, Aksu F et al. Spindle cell sarcomatoid carcinoma: First case reported in the trachea. *Tuberk Toraks* 2009; **57**: 337–41.
- 6 Gurria JP, De Acosta DM, Hafezi N, Yousif EB, AlAmeer E, Anderson RC. Spindle cell sarcomatoid carcinoma of the trachea: First case report of surgical resection. *J Cardiothorac Surg* 2016; **11**: 128.
- 7 Lewis JS, Ritter JH, El-Mofty S. Alternative epithelial markers in sarcomatoid carcinomas of the head and neck, lung, and bladder-p63, MOC-31, and TTF-1. *Mod Pathol* 2005; **18**: 1471–81.
- 8 Thompson L, Chang B, Barsky SH. Monoclonal origins of malignant mixed tumors (carcinosarcomas). Evidence for a divergent histogenesis. *Am J Surg Pathol* 1996; **20**: 277–85.
- 9 Huang SY, Shen SJ, Li XY. Pulmonary sarcomatoid carcinoma: A clinicopathologic study and prognostic analysis of 51 cases. *World J Surg Oncol* 2013; **11**: 252.
- 10 Wright JL, Black PC, Brown GA et al. Differences in survival among patients with sarcomatoid carcinoma, carcinosarcoma and urothelial carcinoma of the bladder. *J Urol* 2007; **178**: 2302–6.
- 11 Travis WD, Brambilla E, Burke A, Marx A, Nicholson AG, eds. *WHO Classification of Tumours of the Lung, Pleura, Thymus and Heart*, 4th edn. IARC Press, Lyon 2015.
- 12 Vered M, Allon I, Buchner A, Dayan D. Clinico-pathologic correlations of myofibroblastic tumors of the oral cavity. II. Myofibroma and myofibromatosis of the oral soft tissues. *J Oral Pathol Med* 2007; **36**: 304–14.
- 13 Qiu X, Montgomery E, Sun B. Inflammatory myofibroblastic tumor and low-grade myofibroblastic sarcoma: A comparative study of clinicopathologic features and further observations on the immunohistochemical profile of myofibroblasts. *Hum Pathol* 2008; **39**: 846–56.
- 14 Hartel PH, Fanburg-Smith JC, Frazier AA et al. Primary pulmonary and mediastinal synovial sarcoma: A clinicopathologic study of 60 cases and comparison with five prior series. *Mod Pathol* 2007; **20**: 760–9.