

Traumatic Epidermal Inclusion Cyst under Anterolateral Thigh Free Flap on Great Toe

Jun Ho Lee, Hwan Jun Choi*

Department of Plastic and Reconstructive Surgery, Soonchunhyang University College of Medicine, Cheonan, Korea

Received March 8, 2015
Revised April 24, 2015
Accepted April 24, 2015

*Correspondence to: Hwan Jun Choi
Department of Plastic and Reconstructive Surgery, Soonchunhyang University Cheonan Hospital, 31 Suncheonhyang 6-gil, Dongnam-gu, Cheonan 330-903, Korea
Tel: +82-41-570-2195
Fax: +82-41-574-6133
E-mail: medi619@hanmail.net

Financial support: This work was supported by the Soonchunhyang University Research Fund.
Conflict of interest: None.

Epidermal inclusion cyst is a common mass in life. It is covered with a stratified squamous epithelium, thus, there is a granular cell layer adjacent to the keratin-containing cyst lumen. It can be caused by mechanical force, trauma, or a spontaneous event. It can rupture spontaneously or be ruptured by external mechanical forces. Epidermal inclusion cysts that exhibit inflammation or recur should be removed by simple excision. In this case, the patient showed an epidermal inclusion cyst under an anterolateral thigh free flap, which can cause the palpable mass to go unnoticed. First we thought he had neuroma formation after a surgical procedure on his foot. However it was an epidermal inclusion cyst, which was diagnosed by a special pathologist. It is a curious and rare case.

Key Words: Epidermal inclusion cyst, Free tissue flaps, Toes, Injuries

Epidermal inclusion cyst is a smooth, dome-shaped, freely movable mass that is attached to the skin by a central pore. It is covered with a stratified squamous epithelium. Thus, there is a granular cell layer adjacent to the keratin-containing cyst lumen. It can be caused by the mechanical force, trauma and spontaneous event. It can rupture spontaneously or be ruptured by external mechanical forces. Epidermal inclusion cysts that exhibit inflammation or recur should be removed by simple excision. In this case, the patient shows the epidermal inclusion cyst under anterolateral thigh (ALT) free flap which can making the palpable mass unnoticed.

CASE REPORT

The 46-year-old man was admitted with a palpable mass with a tingling sensation form medial side of his left great toe

to plantar side of metacarpal area. This symptom had started 2 months ago. Previously, he had trauma by electrical saw and ALT free flap was performed on medial side of his left great toe

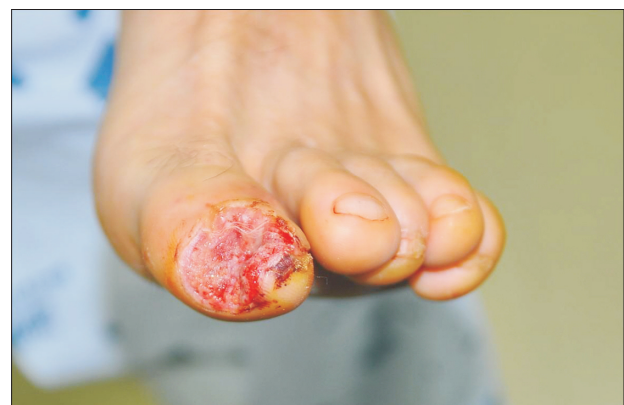

Fig. 1. Skin and soft tissue defect on his left great toe.

due to skin and soft tissue defect on that site two years later (Fig. 1). On physical examination, 1.0×0.8 cm²-sized palpable mass existed on his left great toe (Fig. 2).

He had intermittent pain, numbness, and discomfort. We thought it was post-traumatic neuroma caused by the surgical procedure since neuroma formation is common after invasive surgical treatment. His symptoms failed to respond to conservative measures. So, we planned to perform a surgical operation to relieve his symptoms and signs. The operation (excisional biopsy) revealed a 1.0×0.8 cm²-sized, whitish colored, firm and oval shaped mass with intact capsule wall mass (Fig. 3, 4). There was no evidence of neuroma formation.

As a result of the operation and microscopic evaluation, it was diagnosed as epidermal inclusion cyst. After excision of this cyst, the patient felt relief from his pain. The cyst was under the ALT free flap which masked its characteristics and was the cause of the patient's symptoms.

DISCUSSION

An epidermal inclusion cyst is a smooth, dome-shaped, freely movable, somewhat fluctuant subcutaneous swelling that is covered with a stratified squamous epithelium that resembles the epidermis or the follicular infundibulum. Thus, there is a granular cell layer adjacent to the keratin-containing cyst lumen. Epidermal inclusion cysts can show up at any age. However these cysts rarely happen in children before puberty

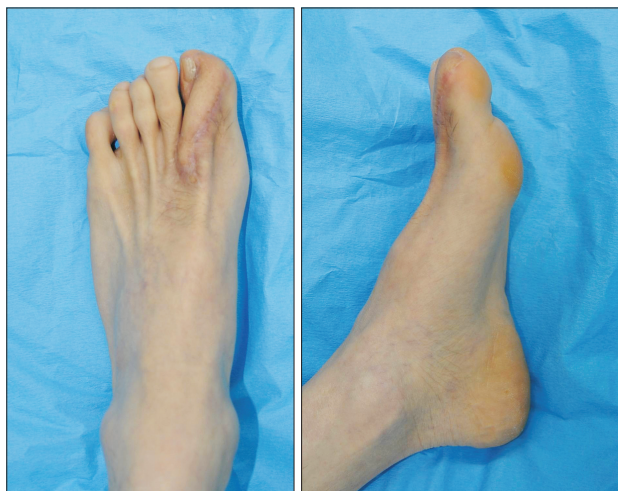


Fig. 2. Anterolateral thigh free flap on his left great toe.

and are usually found in men. It can be caused by mechanical force, trauma or a spontaneous event. Trauma is always the precipitating factor and a source of epithelium capable of proliferation at that time is required. A latent period follows the injury.^{1,2} The cyst is formed when there is proliferation of epidermal cells within an area of the dermis. It may be formed by the traumatic implantation of epidermal cells within the dermis as well as many other mechanisms.³

Post-surgical epidermal inclusion cysts have been reported for multiple procedures, especially those involving a hollow needle which implants a core of tissue into the dermis.⁴ Epidermal inclusion cysts that exhibit inflammation or recur should be removed by simple excision. They commonly present with swelling, pain and tenderness at the affected site.⁵ In this case, the epidermal inclusion cyst existed on the medial side of the patient's left great toe and was under the ALT free flap. The ALT free flap covered the palpable mass. The surgical removal of this mass was achieved without particular difficulties. There is a general consensus that a radical removal of the tumor and its capsule must be achieved in order to prevent the re-growth of the tumor.⁶ Cyst can be removed by excision.⁷ After surgical treatment, his pain and discomfort were relieved.

In a retrospective study, we confirmed he had had another operation, ALT free flap, in the same area. Epidermal inclusion cyst is rare on the sole of the foot and the palm of the hand. In the glabrous skin, the epidermis is generally less innervated.⁸ Injuries to the skin such as traumatic skin damage like smashing

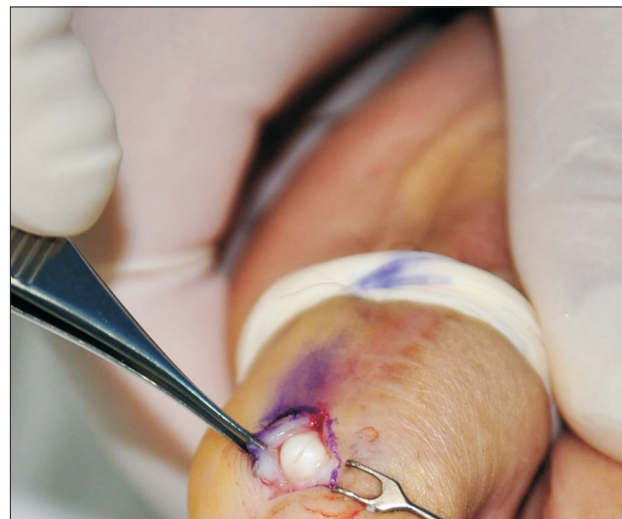

Fig. 3. Mass under Anterolateral thigh free flap.

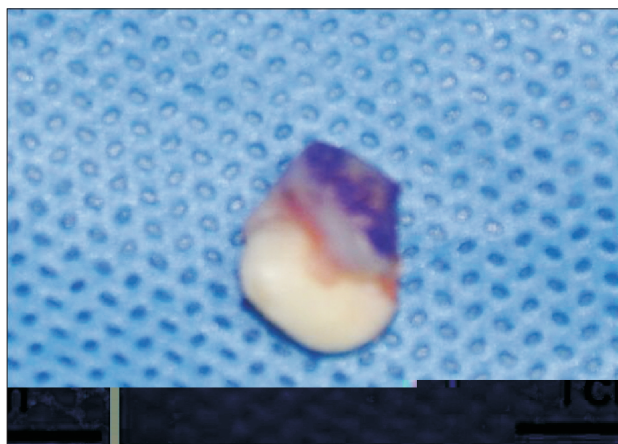


Fig. 4. Epidermal inclusion cyst (1.0×0.8 cm²).

the hand in a door increase the risk of developing epidermal inclusion cysts on that site. In this patient, the saw injury could have been the cause of the injury to the soft tissue on his left great toe. And it can migrate through the epithelium to the defect area. Furthermore, decreased sensation on his great toe due to ALT free flap could mask the existence of this mass. In conclusion, a combination of traumatic injury and surgical procedure can cause the epidermal inclusion cyst to develop in an uncommon area such as under the ALT free flap, which is covered with glabrous skin as seen in this case.

From this case, we learned that, besides the site of the mass, previous procedures have to be considered as important factors.

REFERENCES

1. Turetschek K, Hospodka H, Steiner E. Case report: epidermoid cyst of the floor of the mouth: diagnostic imaging by sonography, computed tomography and magnetic resonance imaging. *Br J Radiol* 1995;68:205-7.
2. Patel K, Bhuiya T, Chen S, Kenan S, Kahn L. Epidermal inclusion cyst of phalanx: a case report and review of the literature. *Skeletal Radiol* 2006;35:861-3.
3. Ishikawa H, Nakai T, Ueda K, Haji S, Takeyama Y, Ohyanagi H. Laparoscopic excision of an epidermoid cyst arising from the deep abdominal wall. *Surg Laparosc Endosc Percutan Tech* 2009;19:e221-4.
4. Low HL, Sivasamy VP, Griffiths AP, Redfern RM. Recurrent carpal tunnel syndrome owing to an implantation epidermoid cyst after carpal tunnel decompression: case report. *Neurosurgery* 2007;60(5):E956.
5. Nakajo M, Ohkubo K, Nandate T, Nagano Y, Shirahama H, Nakajo M. Intraosseous epidermal cyst of the distal phalanx of the thumb: radiographic and magnetic resonance imaging findings. *Radiat Med* 2005;23:128-32.
6. Ugazio P, Mentasti GL, Guffanti E, Perlasca F. Epidermoid cyst of the skull with intradiploetic localization: a case report. *Pediatr Med Chir* 1982;4:455-8.
7. Minimal excision technique for removal of an epidermoid cyst. *Am Fam Physician* 2002;65:1423-4.
8. Hilliges M, Wang L, Johansson O. Ultrastructural evidence for nerve fibers within all vital layers of the human epidermis. *J Invest Dermatol* 1995;104:134-7.