


## Case Report



# Gastrointestinal Perforation Caused by Neodymium Magnet Toys: A Dangerous Foreign Body with Super-Strength

Geum Jong Song , Jong Hyuk Yun , Hae Il Jung , Tae Sung Ahn ,  
Myoung Won Son , Sun Wook Han , Sang Ho Bae , Sung Yong Kim ,  
Moo-Jun Baek , Moon Soo Lee 

Department of Surgery, Soonchunhyang University Cheonan Hospital, Cheonan, Korea

## OPEN ACCESS

Received: Sep 19, 2020

Revised: Oct 30, 2020

Accepted: Nov 16, 2020

### Correspondence to









Myoung Won Son

Department of Surgery, Soonchunhyang University Cheonan Hospital, 31 Soonchunhyang 6-gil, Dongnam-gu, Cheonan 31151, Korea.  
E-mail: mwson@schmc.ac.kr

Copyright © 2020 Korean Association of Pediatric Surgeons

This is an Open Access article distributed under the terms of the Creative Commons Attribution Non-Commercial License (<https://creativecommons.org/licenses/by-nc/4.0>) which permits unrestricted non-commercial use, distribution, and reproduction in any medium, provided the original work is properly cited.

### ORCID iDs

Geum Jong Song   
<https://orcid.org/0000-0002-1067-8099>  
Jong Hyuk Yun   
<https://orcid.org/0000-0002-8746-4945>  
Hae Il Jung   
<https://orcid.org/0000-0003-2502-0086>  
Tae Sung Ahn   
<https://orcid.org/0000-0001-5617-0365>  
Myoung Won Son   
<https://orcid.org/0000-0001-5255-9234>  
Sun Wook Han   
<https://orcid.org/0000-0002-0671-1212>  
Sang Ho Bae   
<https://orcid.org/0000-0003-1138-0013>  
Sung Yong Kim   
<https://orcid.org/0000-0002-2070-0915>

## ABSTRACT

Ingestion of neodymium magnets can cause serious complications in children. Making the decision of treatment is difficult because of nonspecific clinical presentation. We report 2 unusual cases of multiple gastrointestinal perforations with closed loop caused by ingestion of multiple bead-shaped neodymium magnets, which are different from the case caused by ingestion of typical magnets. In the first case, the patient was a 2-year-old boy with multiple jejunal perforations. In the second case, the patient was a 19-month-old girl with gastric and proximal jejunal perforations. Patients presented mild and nonspecific symptoms. Exploratory laparotomy was performed, which led to an uneventful postoperative course in both cases. Popular magnet toys composed of small bead-shaped neodymium magnets have different characteristics from typical magnets. They are enough small to swallow easily with greater magnetic force than typical magnets. When multiple neodymium magnets are ingested, they can attract with greater strength across bowel loops, causing pressure necrosis, perforation. However, patients can only present mild and nonspecific symptoms at the time of visit hospital because perforation sites were sealed by magnets which attract each other with great force. Therefore, surgeons should have a high index of suspicion for gastrointestinal perforation in any patient who has ingested multiple magnets, particularly composed of neodymium, presenting with persistent nonspecific abdominal pain.

**Keywords:** Magnet; Neodymium; Pediatric emergency medicine; Intestinal perforation; Surgery

## INTRODUCTION

Accidental ingestion of magnets is a serious health problem in children. According to statistics published by Korea Consumer Agency, magnet ingestion is the most common magnet-related injury in children, with 188 of 222 cases in Korea between 2013 and 2018, followed by nasal and ear foreign bodies [1]. Recently, neodymium or rare-earth magnets, which are at least 5–10 times more powerful than traditional magnets, have emerged. The popular magnet toys composed of neodymium are multiple small bead-shaped magnets with high power and thus called “small powerful magnet set.” They are small enough for children to swallow easily. Ingestion of multiple neodymium magnets can attract with greater strength

Moo-Jun Baek   
<https://orcid.org/0000-0003-3567-6687>  
 Moon Soo Lee   
<https://orcid.org/0000-0002-3955-1331>

**Funding**

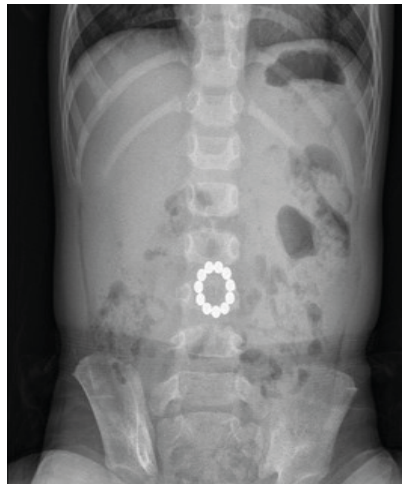
This work was supported by the Soonchunhyang University Research Fund.

**Conflict of Interest**

No potential conflict of interest relevant to this article was reported.

**Author Contributions**

Conceptualization: S.M.W., S.G.J.; Data curation: Y.J.H., J.H.I.; Formal analysis: H.S.W., B.S.H.; Investigation: B.S.H., H.S.W.; Methodology: S.M.W.; Project administration: S.G.J., Y.J.H.; Supervision: K.S.Y.; Validation: B.M.J., L.M.S.; Writing - original draft: S.G.J., Y.J.H., A.T.S.; Writing - review & editing: S.M.W., B.M.J., L.M.S.



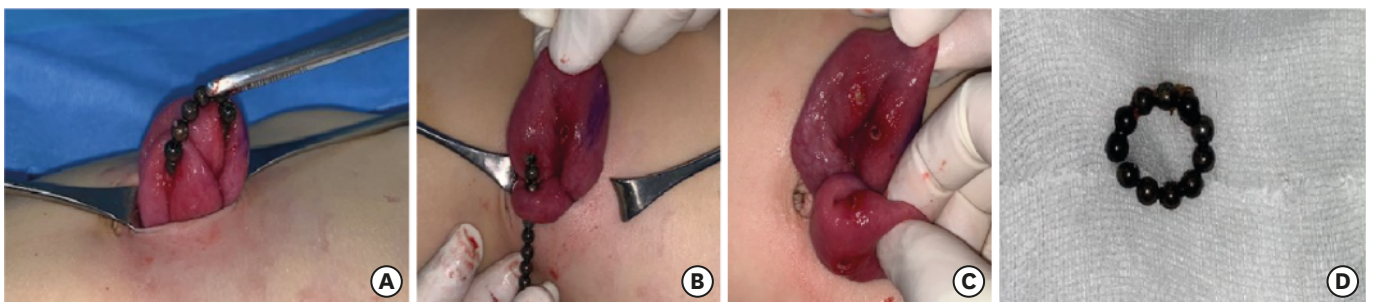
**Fig. 1.** Abdominal X-ray demonstrating 11 bead-shaped magnets in mid abdomen.

across bowel loops. It causes pressure necrosis of the bowel wall and subsequent perforation [2]. Herein, we present 2 cases of closed loop perforations due to neodymium magnet bead ingestion, which are different from the case caused by ingestion of typical magnets.

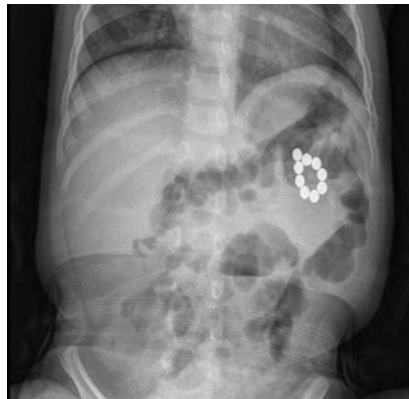
**CASE REPORT**

**1. Case 1**

A 2-year-old boy presented with abdominal pain and bilious vomiting for 6 days. He had a fever for 3 days. He ingested multiple bead-shaped magnetic toys. On admission, he had abdominal pain and mild fever (body temperature, 37.5°C). His abdomen was soft, mildly tender, and not distended on physical examination. Laboratory findings were normal. Abdominal radiography revealed no free air and 11 bead-shaped magnets arranged in a circle (Fig. 1). Serial radiographs were followed up for 2 days. They showed no significant change in the position of the magnets, and the abdominal pain did not improve. Therefore, exploratory laparotomy was performed. Multiple perforations of the jejunum caused by the loops of magnets were found approximately 15 and 35 cm distal to the Treitz ligament. It was not appropriate to perform primary repair because there are too many perforation sites in the short bowel loop and discoloration was observed. Twenty-five cm of the jejunum, including all 5 perforation sites, was resected, and a primary anastomosis was made (Fig. 2). He had an uneventful postoperative recovery course and was discharged on the fifth postoperative day.



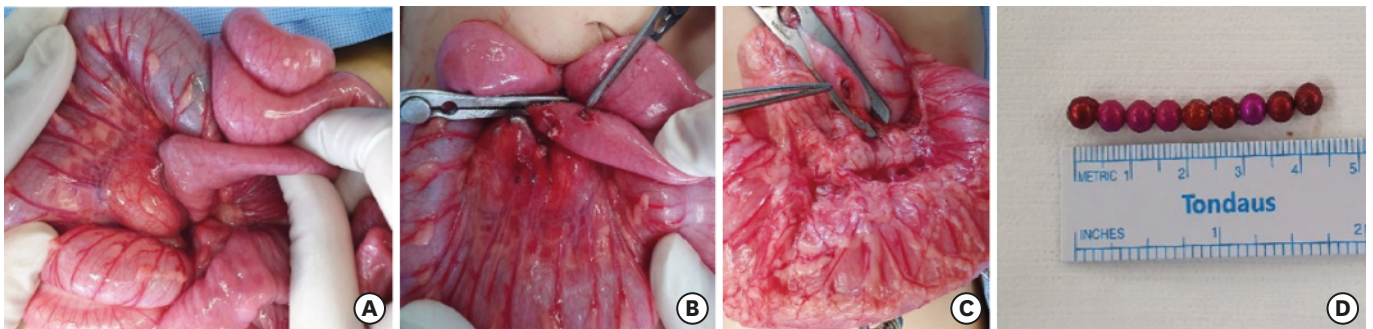
**Fig. 2.** (A, B) Multiple jejunal perforations caused by bead-shaped magnets. (C) Two perforation sites in each part of jejunum. (D) Eleven bead-shaped magnets arranged in a circle.



**Fig. 3.** Abdominal X-ray demonstrating 9 bead-shaped magnets in left upper abdomen.

## 2. Case 2

A 19-month-old girl presented with abdominal pain and mild fever for 3 days. She had been treated at another clinic, and foreign bodies were accidentally found on abdominal radiography because her parents had not seen her ingesting the magnets. Abdominal radiography revealed 9 bead-shaped magnets arranged in a circle (**Fig. 3**). She was transferred to our institution for proper management. Her symptoms were not severe but did not improve. On physical examination, her abdomen was soft, mildly tender, and non-distended. Her C-reactive protein level at admission was elevated (35.66 mg/L), and other laboratory findings were nonspecific. She had been examined with repeated abdominal radiographies for 1 day after admission, which revealed no significant change in the position of magnets. Therefore, exploratory laparotomy was performed. Magnets were found in the stomach and proximal jejunum, approximately 5 cm distal to the Treitz ligament, adducting toward each other through the transverse mesocolon (**Fig. 4**). Necrotic segments of the gastric perforation site were excised, and primary closure with an omental patch was performed. Wedge resection of the jejunum, including the 2 perforation sites, was performed using a linear stapler. She had an uneventful postoperative recovery course and was discharged on the fifth postoperative day. The need for ethic approval is not subject to the institutional review board (local ethics committee) due to simple case reporting. Written informed consent was obtained from the patient's parents in both cases to report and publish individual patient data.



**Fig. 4.** (A-C) There was transverse mesocolon between jejunum and stomach. Multiple magnets caused pressure necrosis and multiple perforations in jejunum and stomach but could not penetrate transverse mesocolon. (D) Nine bead-shaped magnets arranged in a line.

## DISCUSSION

Ingestion of foreign bodies is a common problem in the pediatric population. More than 3-quarters of such cases occurred in children, mostly in those aged between 6 months and 3 years. Its occurrence has been steadily increasing. Most foreign bodies passed down to the stomach or more distal bowels are excreted in feces spontaneously without any treatment [3,4].

When ingested, magnetic objects are harmful and require special consideration. Ingestion of a single magnet usually does not cause a problem. A single ingested magnet can be managed conservatively with appropriate education of the parents and child. It is possible for magnets to attract together, overlap on a single view, and be misdiagnosed as a single magnet. Serial radiographs should be considered to determine whether a single magnet is truly present. However, ingestion of multiple magnets or a single magnet with other metallic objects can be harmful. They can attract each other, forcefully dragging the bowel walls by exerting pressure. Eventually, they lead to pressure necrosis, peritonitis, gastrointestinal tract perforation, fistula, or intestinal obstruction [5-7].

Therefore, noting the history is important in cases of magnet ingestion, and the number of magnets ingested must be determined. Child with nonspecific abdominal symptoms may have swallowed the foreign bodies without their parents witnessing, as in our second case. Early detection of magnet ingestion is important because magnets localized to the stomach can be removed endoscopically to minimize morbidity [8,9].

In our cases, physical examination revealed a soft, mildly tender non-distended abdomen, but the operative findings showed multiple gastrointestinal perforations. For patients with multiple magnetic foreign bodies, which can cause harmful gastrointestinal complications, including fistula or perforation, operative intervention should be considered even in asymptomatic patients [7]. Neodymium magnets can cause injuries to multiple organs because they are so small but stronger than typical magnets. As in our cases, small bead-shape magnets can line in a circle through multiple organs; therefore, care should be taken not to miss damaged areas.

The current incidence of magnet ingestion in the pediatric population has increased >3 times from that in the early 2000s in Korea. Many of other countries have similar situations and recalled many products that did not meet the standards, mostly small powerful magnet sets, which include many small neodymium magnets of approximately 3–5 mm in size [1,2,6]. Our 2 cases were caused by a small powerful magnet set. All products containing magnets must meet the standards of being large enough to be unswallowable and have weak magnetic force ( $<50 \text{ kG}^2 \text{ mm}^2$ ) [1,10]. Magnet-related products must be tightly regulated and monitored and recalled immediately when they do not meet the standards.

Recently, popular magnet toys composed of small bead-shaped neodymium magnets have been sold without proper regulation. When multiple magnets are ingested, they can attract with greater strength across bowel loops, causing pressure necrosis, perforation, or fistula. Surgeons should be aware of the potential for gastrointestinal perforation from multiple magnets ingestion in all patients, not just in patients presenting with symptoms of peritonitis. Patients can only present mild and nonspecific symptoms at the time of visit hospital because perforation sites were sealed by magnets which attract each other with great force. Therefore, for children with nonspecific abdominal symptoms, the first step should

be thorough history taking and specifically inquiring about possible foreign body ingestion. If the history is positive or highly suspicious, abdominal radiography or ultrasonography should be performed [9]. A high index of suspicion is important for gastrointestinal perforation in any patient who has ingested multiple magnets presenting with persistent nonspecific abdominal pain.

## REFERENCES

1. Korea Cosumer Agency. A survey on safety of magnetic toys for kids [Internet]. Eumsung: Korea Cosumer Agency; c2018 [cited 2018 Jul 5]. Available from: <https://www.kca.go.kr/home/sub.do?menukey=4062&mode=view&no=1002670650&page=9>.
2. Hussain SZ, Bousvaros A, Gilger M, Mamula P, Gupta S, Kramer R, et al. Management of ingested magnets in children. *J Pediatr Gastroenterol Nutr* 2012;55:239-42.  
[PUBMED](#) | [CROSSREF](#)
3. Sahin C, Alver D, Gulcin N, Kurt G, Celayir AC. A rare cause of intestinal perforation: ingestion of magnet. *World J Pediatr* 2010;6:369-71.  
[PUBMED](#) | [CROSSREF](#)
4. Brown JC, Otjen JP, Drugas GT. Too attractive: the growing problem of magnet ingestions in children. *Pediatr Emerg Care* 2013;29:1170-4.  
[PUBMED](#) | [CROSSREF](#)
5. Chung JH, Kim JS, Song YT. Small bowel complication caused by magnetic foreign body ingestion of children: two case reports. *J Pediatr Surg* 2003;38:1548-50.  
[PUBMED](#) | [CROSSREF](#)
6. Sola R Jr, Rosenfeld EH, Yu YR, St Peter SD, Shah SR. Magnet foreign body ingestion: rare occurrence but big consequences. *J Pediatr Surg* 2018;53:1815-9.  
[PUBMED](#) | [CROSSREF](#)
7. George AT, Motiwale S. Magnets, children and the bowel: a dangerous attraction? *World J Gastroenterol* 2012;18:5324-8.  
[PUBMED](#) | [CROSSREF](#)
8. Tavarez MM, Saladino RA, Gaines BA, Manole MD. Prevalence, clinical features and management of pediatric magnetic foreign body ingestions. *J Emerg Med* 2013;44:261-8.  
[PUBMED](#) | [CROSSREF](#)
9. Bauman B, McEachron K, Goldman D, Louiselle A, Zheng E, Mills D, et al. Emergency management of the ingested magnet: an algorithmic approach. *Pediatr Emerg Care* 2019;35:E141-4.  
[PUBMED](#) | [CROSSREF](#)
10. Reeves PT, Nylund CM, Krishnamurthy J, Noel RA, Abbas MI. Trends of magnet ingestion in children, an ironic attraction. *J Pediatr Gastroenterol Nutr* 2018;66:e116-21.  
[PUBMED](#) | [CROSSREF](#)