

후천성면역결핍증후군 환자에서의 저온 접촉 화상에 의한 삼도 화상의 치료

홍석원¹ · 최환준^{1,2} · 김준혁¹ · 이다운¹

¹순천향대학교병원 성형외과, ²순천향대학교병원 재생의학회

Treatment of Third Degree Burn due to Low-Temperature Contact Burn on Acquired Immune Deficiency Syndrome (AIDS) Patient: Low-Temperature Burn on AIDS Patient

Seok Won Hong, M.D.¹, Hwan Jun Choi, M.D., Ph.D.^{1,2}, Jun Hyuk Kim, M.D., Ph.D.¹ and Da Woon Lee, M.D.¹

¹Department of Plastic and Reconstructive Surgery, College of Medicine, Soonchunhyang University, ²Institute of Tissue Regeneration, Soonchunhyang University, Cheonan, Korea

Incidence of low-temperature contact burn by use of an electric pad is increased recently, especially in depressed sensory. Acquired immune deficiency syndrome patient using antiretroviral agent suffered with sensory depression as side effect. There are many limitations in wounds treatment of these patients. These patients are vulnerable to infection due to their weak immunity, so it is necessary to keep them in a state of isolation when a wound occurs. We report a case of a third degree burn by electric pad with a surface area of approximately 5% of the body surface of a patient who underwent a sensory depression, which is a side effect of antiretroviral drugs used for treatment in patients with AIDS. In this regard, we report the case with literature review, which is safely recovered using negative-pressure wound therapy and split-thickness skin graft. (**J Korean Burn Soc 2019;22:21-24**)

Key Words: Burns, Acquired immunodeficiency syndrome, Reconstructive surgical procedures

INTRODUCTION

There is no clear definition of the term with low-temperature burn. Generally, it refers to burn in the low temperature that has occurred for a long contact time causing the rise of temperature and accumulation of damage. According to the journal of American Burn Association, in case of scalding burn, deep burns can be occurred at 44°C after elapsing 6 hours and 45°C after elapsing 3 hours¹⁾. There is a research report that deep burns may occur only in 1 second at above 68°C¹⁾.

Unlike the West, which used the convection of warm air using a fireplace for heating in winter, Korea recently preferred to use electric pad in the floor as well as bed due to the cultural influence of heating with the warm Ondol in winter. These electric plates are usually set at a temperature of 40°C to 50°C which is sufficient to be burned. In general, high-temperature burns can be treated quickly because of symptoms such as pain and discomfort. In the case of low-temperature contact burns, however, pain or discomfort is not so severe or cannot be detected, so that the burns can be deeply processed. As the incidence of low-temperature burns has increased recently, it has been reported that healthy people who are not taking alcohol and have no chronic diseases such as diabetes can get third degree burns at the time of sleeping²⁾. Severe burns may occur or get worse easily, especially in patients with reduced sensation or weak skin.

There are many limitations in wounds treatment of patients with acquired immune deficiency syndrome (AIDS). AIDS patients are vulnerable to infection due to their

Received: 2019. 5. 28, Revised: 2019. 7. 30, Accepted: 2019. 9. 11
Corresponding author: Hwan Jun Choi, Department of Plastic and Reconstructive Surgery, Soonchunhyang University Cheonan Hospital, 31 Sooncheonhyang 6-gil, Dongnam-gu, Cheonan 31151, Korea
Tel: 82-41-570-2195, Fax: 82-41-574-6133
E-mail: iprskorea@gmail.com

This work was supported by the Soonchunhyang University Research Fund.

weak immunity, so it is necessary to keep them in a state of isolation when a wound occurs. Care should be taken as it is slower to recover than in healthy people and can lead to sepsis if infection occurs. From the perspective of a healthy care staff who has to treat these patients, they are exposed to the risk of infection of blood through needles or syringes. Medical staff should consider and proceed treatment through the safe way to protect themselves and other patients from this.

We report a case of a 3rd degree burn by electric pad with a surface area of approximately 5% of the body surface of a patient who underwent a sensory depression, which is a side effect of antiretroviral drugs used for treatment in patients with AIDS. In this regard, we report the case with literature review, which is safely recovered using negative-pressure wound therapy and split-thickness skin graft.

CASE REPORT

A 46-year old male patient who had diagnosed acquired immune deficiency syndrome (AIDS) was treated by antiretroviral drugs and undergone nausea and hyposthesia of lower extremities caused by side effect of the treatment. The patient developed a burn on the right lower limb after sleeping on the electrical pad, but was self-disinfected at home. The wound was not recovered and worsened, and the patient was admitted to the out-

patient clinic of department of infectious disease which was visited regularly. There was no specific medical history except AIDS. At the time of admission, the wounds were found to be covered with focal eschar formation and marginal induration in a wide range of about 5% of the body surface area of the right lower limb. Some of tendons were exposed and there was depression of tactile and pain sensation (Fig. 1). Preferentially, patient was reverse isolated and checked overall status. He didn't have fever and general condition was well. Overall laboratory blood examination was done. Specifically, Procalcitonin rate was reported 20.380 ng/mL and C-reactive protein rate was reported 190.89 mg/L. We treated the wound and intravenous antibiotic treatment using Cefepime with close consultation between the Department of Infectious Disease and Plastic Surgery considering medical condition of the patient. When the patient was judged to be undergoing surgical treatment, we performed the eschar-ectomy and debridement of the wound. Focal necrosis of the muscle layer and subcutaneous layer was observed. Early negative pressure wound therapy (NPWT) using the Vacuum Assisted Closure™ device (CuraV.A.C.® Therapy, CGBIO, South Korea) was performed to minimize the movement and contact of the patient. In order to prevent infection through the blood of the patient, the operation was carried out while wearing safety glasses, special mask and double-gloving. NPWT was done twice a week for 3 weeks (Fig. 2). 24 days after admission, there

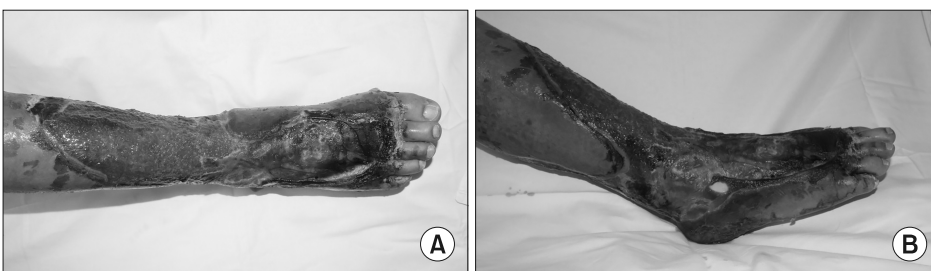


Fig. 1. On admission images: 3rd degree burn on right lower leg with eschar formation and focal tendon exposure, (A) anterior images (B) lateral images.

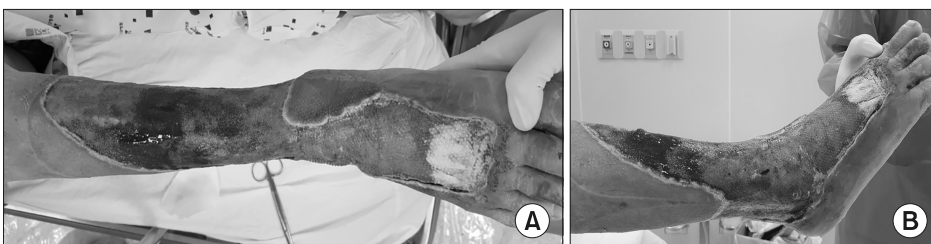


Fig. 2. 6 times after NPWT images: defect site covered by healthy granulation tissue (A) anterior images (B) lateral images.

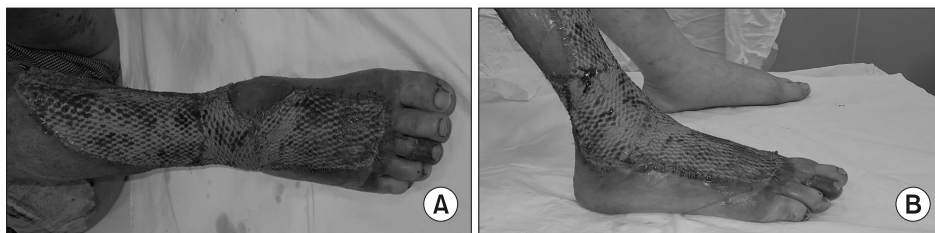


Fig. 3. 5 days after mesh STSG and NPWT images: skin graft was stable and almost taken state (A) anterior images (B) lateral images.

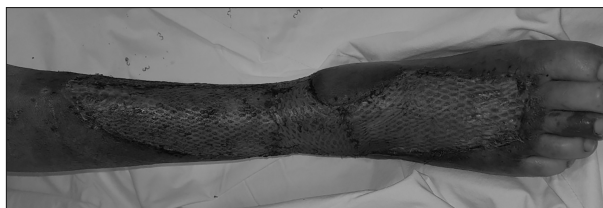

Fig. 4. 8 days after mesh STSG and NPWT images: skin graft was stable.

was no infection sign with healthy granulation tissue and split thickness skin graft using mesh was performed. Intermediate thickness of skin graft was taken and be widened by using 1:1.5 ratio Mesh plate. Focal tendon exposure site was covered with acellular dermal matrix (Matriderm[®], Medskin solutions, US) and skin graft. NPWT was performed on the skin graft site for minimizing the movement and contact of the patient. The pressure of NPWT was 75 mmHg. To protect the skin graft from detaching with sponge of NPWT, we cover the skin graft with lubricous perforated material (Mepitel One[®], Molnlycke Health Care[®], US) (Fig. 3). Five days after the operation, the skin graft was almost taken except focally lost. Eight days after operation, the patient was nearly healed without any complications and discharged (Fig. 4).

DISCUSSION

Unlike the West, which used the convection of warm air using a fireplace for heating in winter, Korea recently preferred to use electric pad in the floor as well as bed due to the cultural influence of heating with the warm Ondol in winter. Because the surface temperature of current electrical pads is usually limited to 50°C, in the absence of underlying disease, it is not uncommon to take burns, but occasional cases of severe burn have been observed when the senses are diminished or sleeping pills are taken. Recently, one research has been conducted as

increasing the number of cases of severe burn by electric pads and a paper reported that even a healthy person without medical or specific history such as taking sleeping pills or drunken state may experience burns due to electric pads²⁾.

Low-temperature burn can be occurred by various media, but in general, the most frequent cases are caused by contact and hot water in the outpatient department of hospital. There have been various studies on generation and aggravation of burn. According to Brans et al.³⁾, the contact burn results in a severe burn compared to the scalding burn when the burn is taken at the same time and at the same temperature. This suggests that the low-temperature contact burn may result in a severe burn even with a shorter exposure time.

Generally, it is reported that deep burns can occur when the scalding burn from 44°C to 6 hours and from 45°C to 3 hours. While, the low-temperature contact burn can be caused more severe burn even with a shorter exposure time at the same temperature^{1,3)}. From the study of Kim et al.²⁾, the surface temperature was measured in silicone rubber with a thermal conductivity similar to that of human skin at seven state of electric pad (130 W, 1~7 state temperature controller). As a result, the temperature rise to 45.5°C after 7 hours, and to 58.1°C when the blanket was additionally covered. This is a temperature at which severe burn can be occurred within one minute.

Antiretroviral therapy which has greatly improved prognosis of HIV infection is combinations of the drugs to avoid viral resistance. Adverse reactions are common with antiretrovirals such as hypersensitivity reactions, liver toxicity, gastrointestinal intolerance and nervous system toxicity. Peripheral neuropathy can be occurred as side effect of antiretroviral therapy⁴⁾. In our case, the patient had undergone the hypoesthesia of both lower leg due to the therapy. As we mentioned above, prevention through education is very important in patients with de-

creased sensation, especially because of the high probability of occurrence of low-temperature contact burn.

Treatment of over third degree burns in AIDS patients has many limitations and risks. Patients with impaired immune status and without proper treatment may experience worsening of wound resulting sepsis and opportunistic infections. Therefore, it is important to select adequate methods of treatment. These methods should be done in extreme sterility. Recovery from simple wound dressing can be a time-consuming and unsuitable choice for AIDS with weak immunity. This can also be a burden to the medical staff with risks of infection.

Health care staff always exposure to the risk of biohazardous transmission in surgery of any infectious patient. Despite the highest standards of infection control, including universal safety precautions, there remains a risk of needle-stick injury to the operating room staff. A systematic review suggested a per-event risk of 23 of 10,000 cases of HIV transmission from needle-stick injury⁵⁾. In our report, to minimize the procedures and frequency for reducing the risk of transmission and maximize the effect of treatment for patient, we performed the negative pressure wound therapy. Whenever surgical treatment was performed, all instruments including the walls of the operating room, were covered with plastic bags to prevent to transferring the blood of AIDS patient to others through instruments. Also, we take every efforts to minimize the potential for needle-stick injury, including the passing of any sharp instrument in a sterile container,

which is transferred as needed from surgeons to the scrub nurse. We strongly recommend “Double-gloving” for all cases of the procedures in operating room to reduce medical staff percutaneous blood exposure.

It is considered that the low-temperature contact burn due to the electric pad can be occurred with a higher probability than the healthy person for the person with the sensory depression. By educating and preventing this, it is considered that the incidence of severe burn can be lowered. If these burns occur in AIDS patients despite such education and prevention, as in our report, early surgical treatment, negative pressure wound therapy and recovery through skin graft using mesh are expected to minimize the burden on patients and medical staff and result in good prognosis.

REFERENCES

- 1) American Burn Association. Scald injury prevention : Educator's guide. 2008;3
- 2) Seungsoo Kim, et al. The mechanism of low temperature burn and clinical cases. *J Korean Burn Soc* 2015;18:74-80.
- 3) Brans T, Dutrieux R, Hoekstra M, Kreis R, Pont J. Histopathological evaluation of scalds and contact burns in the pig model. *Burns*. 1994;20:48-51.
- 4) Bernardino R. Adverse drug reactions to antiretroviral medication. *Frontiers in Bioscience* 14. 2009:1785-1792
- 5) Marcus JL, Chao CR, Leyden WA, et al. Narrowing the gap in life expectancy between HIV-infected and HIV-uninfected individuals with access to care. *J Acquir Immune Defic Syndr* 2016;73:39-46.