

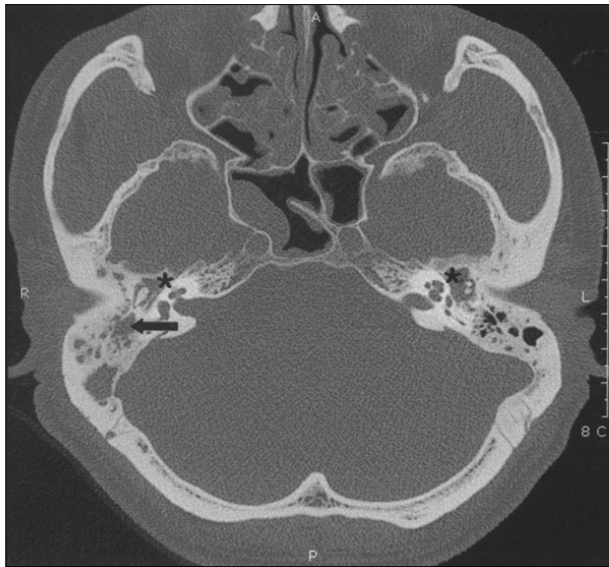Fig. 1. Axial CT scan of the temporal bone showing soft tissue density of middle ear (astro) and mastoid cavity (black arrow).

가  
1~2  
2  
1  
2~3

1952 Derlacki<sup>3)</sup>가  
'middle ear allergy'  
가 가  
. 1967 Shambaugh Glasscock<sup>2)</sup> 'Allergic otitis  
media', 1995 Matsutani<sup>4)</sup>

2  
(Fig. 3),

(Fig. 4).

가

가

, Theophylline

2 :

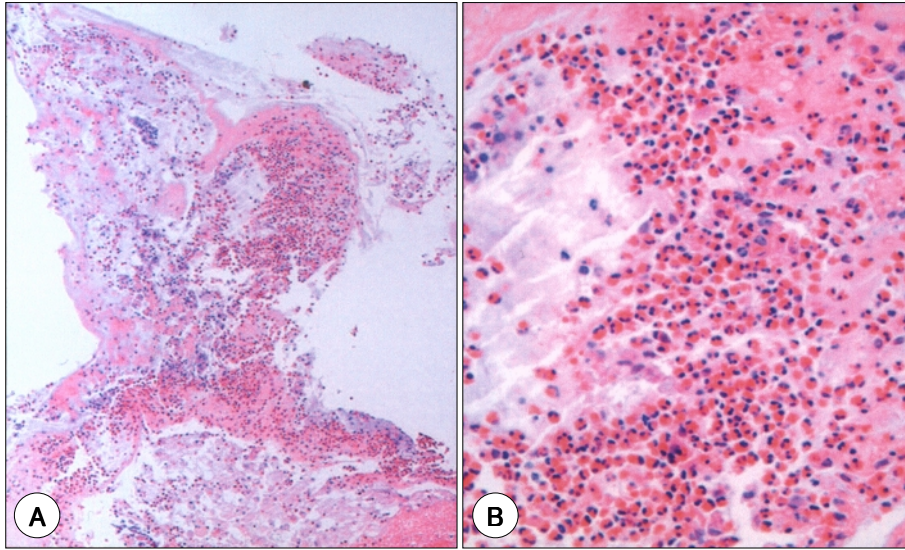
54

. 4

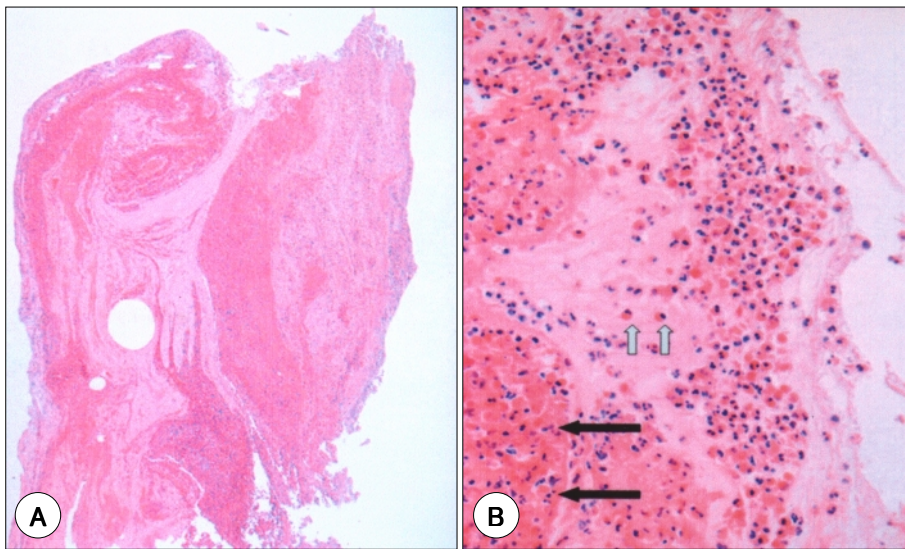
54 dB,  
48 dB,

18 dB ,  
16 dB ,

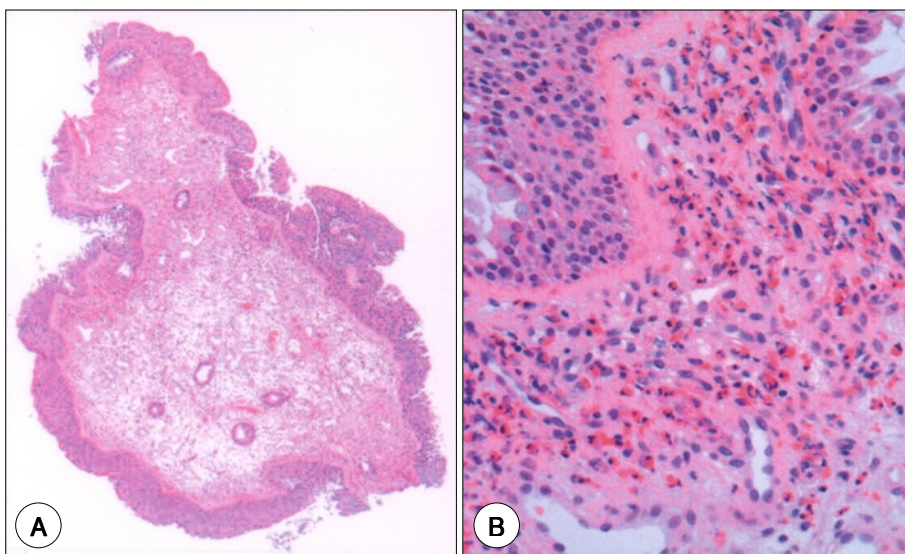
가 ,  
. 1996 Morinaka<sup>5)</sup>  
가 가  
가  
42%  
36%  
6)  
가 가  
'shock organ'  
IgE 가  
10  
0.05~0.12 가 가  
20 가  
10  
1.5 ,  
50~60



**Fig. 2.** A : Mucopurulent exudate from middle ear containing numerous eosinophils (H & E,  $\times 100$ ). B : High power view of the eosinophils (H & E,  $\times 400$ ).



**Fig. 3.** A : A fragment of tissue from middle ear cavity containing mucoid material and numerous eosinophils (H & E,  $\times 10$ ). B : High power view of degenerated eosinophils (black arrows) and the non-degenerated eosinophils (white arrows) (H & E,  $\times 400$ ).



**Fig. 4.** A : Nasal polyp showing squamous metaplasia and inflamed and edematous stroma (H & E,  $\times 10$ ). B : High power view of the subepithelial eosinophils (H & E,  $\times 400$ ).



3)8)16)

3

REFERENCES

1) Matsutani S. *Concept and diagnosis of eosinophilic otitis media*. *Otol Jpn* 2004;14:108-11.

2) Shambaugh GE, Glasscock ME. *Surgery of the ear*. 3rd ed. USA: Saunders;1980. p.207-8.

3) Derlacki E. *Aural manifestation of allergy*. *Ann Otol Rhinol Laryngol* 1952;61:179-88.

4) Matsutani S, Kobayashi T, Takasaka T. *Intractable otitis media in patients with bronchial asthma - (Eosinophilic otitis media)*. *Otolaryngol-HNS* 1995;67:712-3.

5) Morinaka S. *Allergic otitis media with gelatinous mucoid fluid containing eosinophils*. *Otolaryngol Head Neck Surg* 1996;114:665-8.

6) Mogi G, Suzuki M. *The role of IgE-mediated immunity in otitis media: Fact or fiction?* *Ann New York Acad Sci* 1997;830:61-9.

7) Iino Y, Nagamine H, Yabe T, Matsutani S. *Eosinophils are activated in middle ear mucosa and middle ear effusion of patients with intractable otitis media associated with bronchial asthma*. *Clin Exp Allergy* 2001;31:1135-43.

8) Nagamine H, Iino Y, Kojima C, Miyajawa T, Iida T. *Clinical characteristics of so called eosinophilic otitis media*. *Auris Nasus Larynx* 2002;29:19-28.

9) Suzuki H, Matsutani S, Kawase T, Iino Y, Kawauchi H, Gyo K, et al. *Epidemiologic Surveillance of 'Eosinophilic Otitis Media' in Japan*. *Otol Jpn* 2004;14:112-7.

10) Matsutani S. *A case report of eosinophilic otitis media arising after nasal surgery*. *The Allergy in Practice* 2003;23:78-81.

11) 小林 俊光. *好酸球性中耳炎の基礎と臨床, 司會のことば*. *Otol Japan* 2004;14:107

12) Hurst DS. *Association of otitis media with effusion and allergy as demonstrated by intradermal skin testing and eosinophil cationic protein levels in both middle ear effusion and mucosal biopsies*. *Laryngoscope* 1996;106:1128-37.

13) Schwartz RH, Puglese J, Schwartz DM. *Use of a short course of prednisone for treating middle ear effusion*. *Ann Otol Rhinol Laryngol* 1980;89:296-300.

14) Kubo M. *Intratympanic application of hydrocortisone for the treatment of otitis media with effusion [in Japanese]*. *Pract Otol (Kyoto)* 1961;54:456-8.

15) Zanussi C, Ortolani C, Pastorello E. *Dietary and pharmacologic management of food intolerance in adults*. *Ann Allergy* 1983;51:307-10.

16) Miyamoto I, Kanda Y, Yoshida H, Kihara C, Shigeno K, Kobayashi T, et al. *Eosinophilic Otitis Media with Cochlear Dysfunction: -An Investigation into a Cochlear Implant Patient-*. *Audiology Japan* 2003; 46:123-8.